Lower end of femur

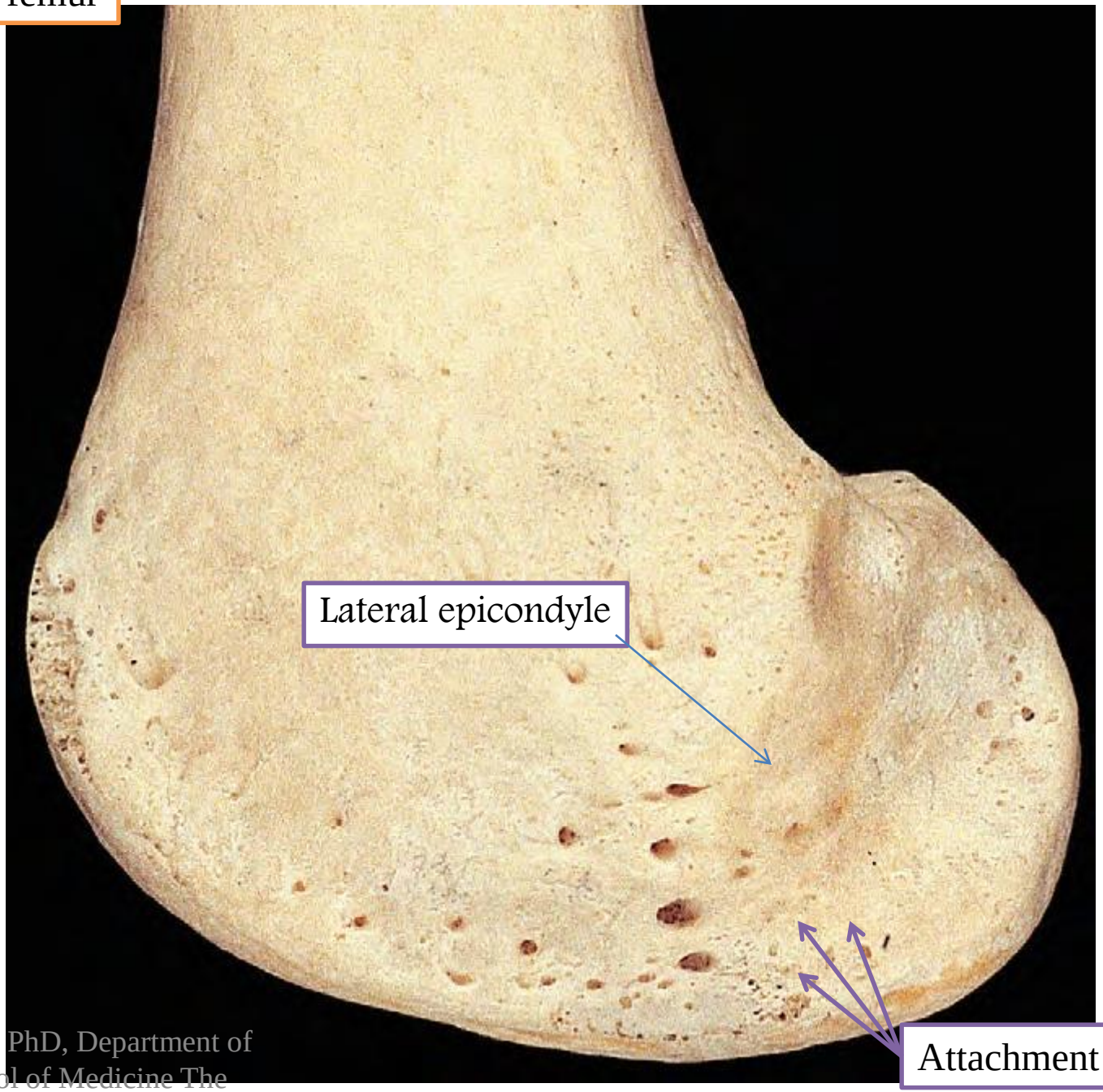

Dr. Shatarat, MD. PhD, Department of Anatomy, School of Medicine The University of Jordan

Left patella: anterior aspect.

Its anterior surface is subcutaneous

Area of attachment of vastus intermedius.

Area of attachment of rectus femoris.

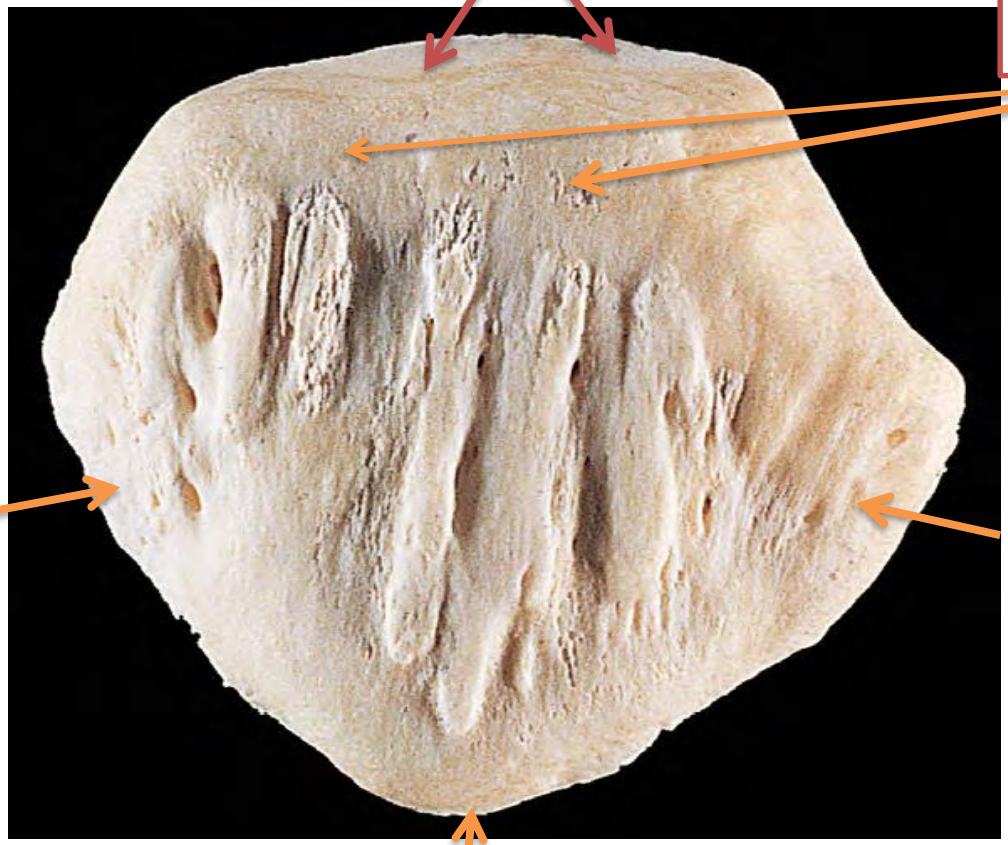

Medial border: attachment of medial retinaculum (expansion).

Lateral border: attachment of lateral retinaculum (expansion).

Apex

Dr. Shatarat, MD. PhD,
Department of Anatomy, School of Medicine The University of Jordan

Left patella: articular (posterior) surface.

is smooth, with a smaller medial and a larger lateral facet for articulation with the femoral condyles

lateral facet

Medial facet



Area for attachment of patellar tendon.

Dr. Shatarat, MD. PhD,
Department of Anatomy

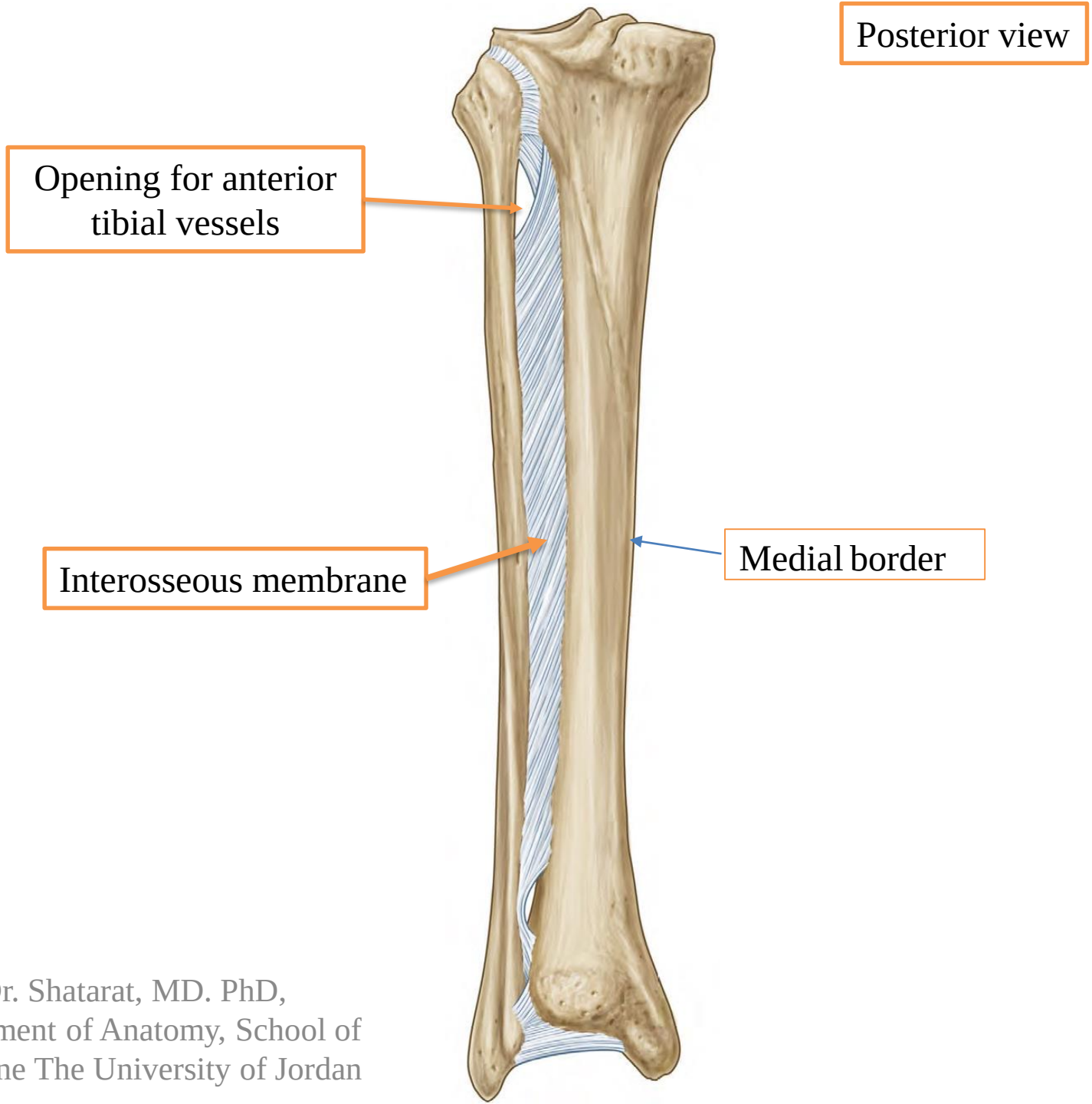

Dr. Shatarat, MD. PhD,
Department of Anatomy, School of Medicine The University of Jordan

Anterior view

Medial condyle

Lateral condyle

Tuberosity Of Tibia

Lateral surface

Interosseous border
Directed laterally

Anterior border
shin tibia

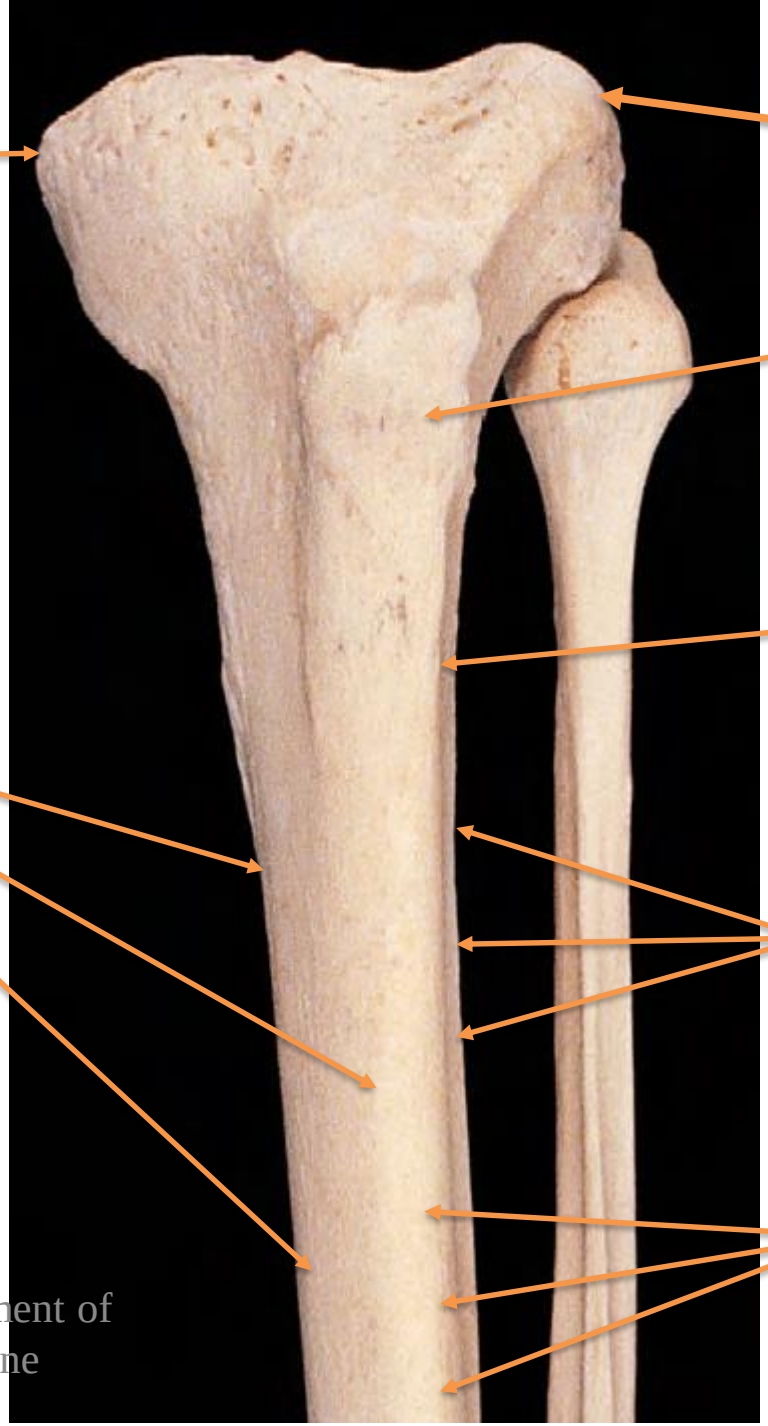

The shaft of the tibia is subcutaneous and unprotected anteromedially throughout its course.
It is not surprising that the tibia is the commonest long bone to be fractured.
The extensive subcutaneous surface of the tibia makes it an accessible donor site for bone- grafts

Dr. Shatarat, MD. PhD, Department of Anatomy, School of Medicine
The University of Jordan

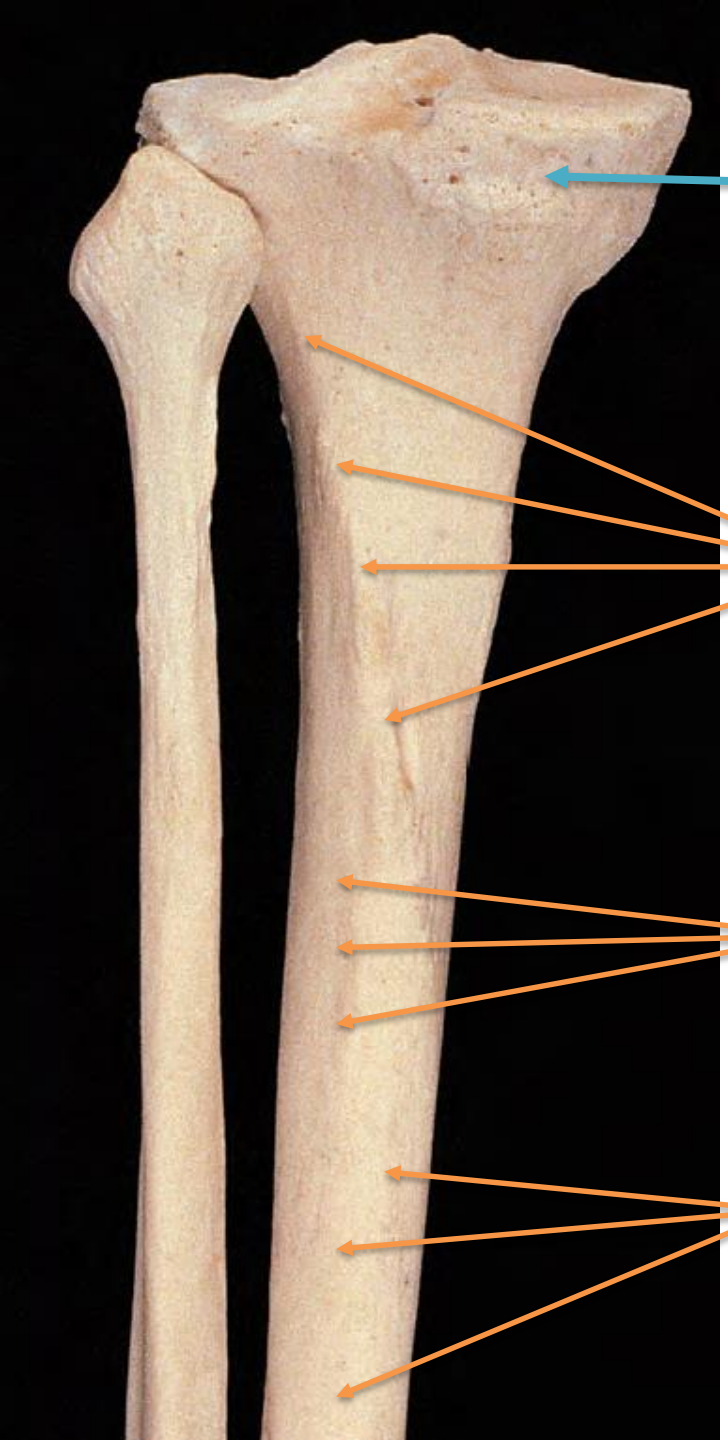

Dr. Shatarat, MD. PhD,
Department of Anatomy, School of Medicine The University of Jordan

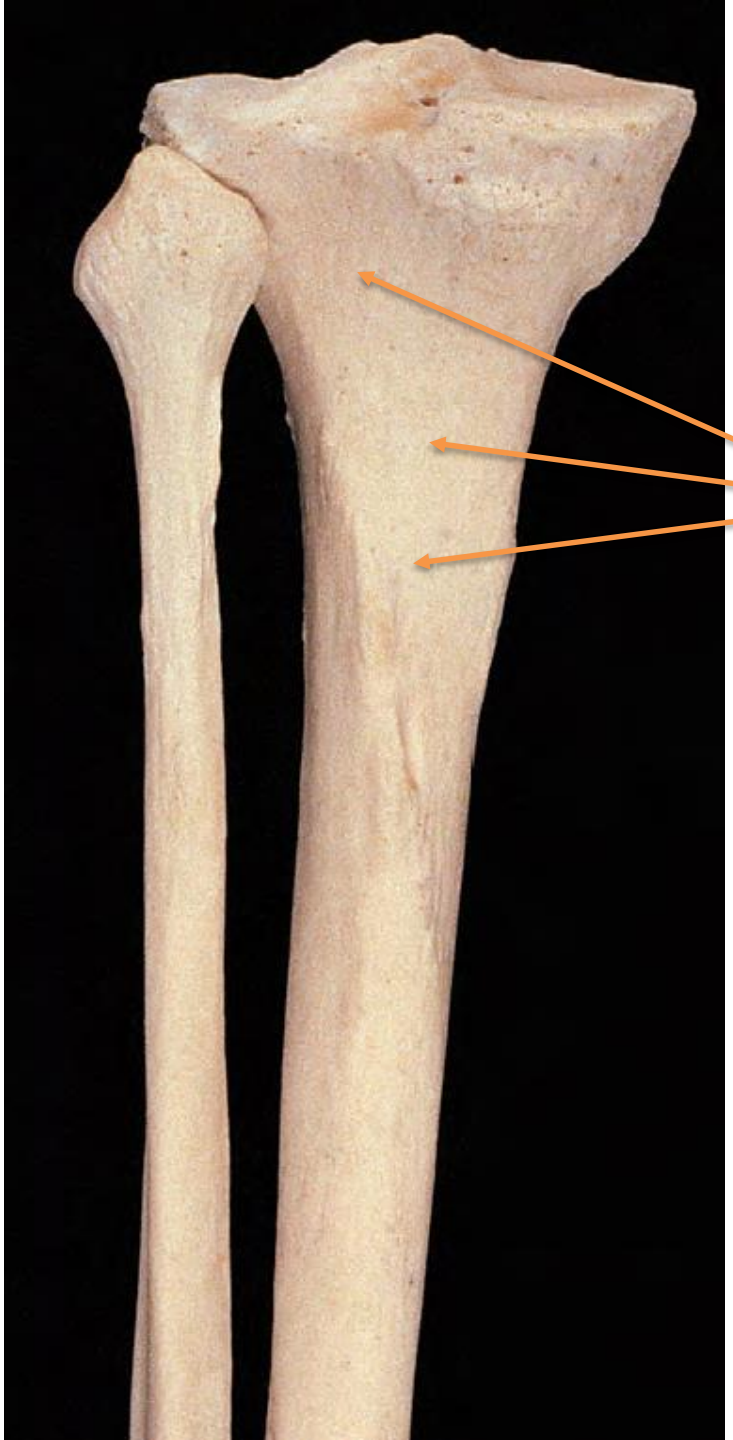

Dr. Shatarat, MD. PhD, Department of Anatomy, School of Medicine The University of Jordan

Groove for tibialis posterior muscle

Dr. Shatarat, MD. PhD, Department of Anatomy, School of Medicine The University of Jordan

The upper end of fibula

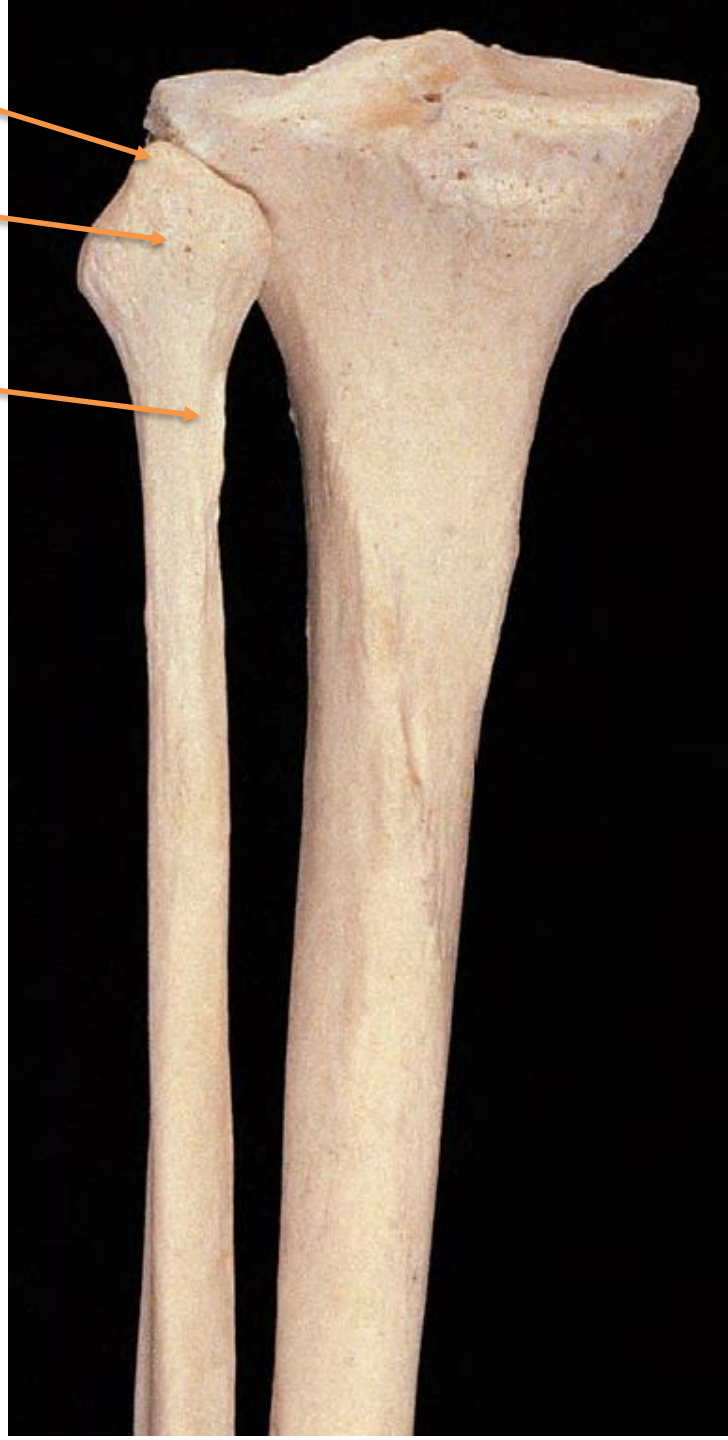

Dr. Shatarat, MD. PhD,
Department of Anatomy,
School of Medicine The
University of Jordan

Shaft of fibula

Three surfaces

Articular facet of the head

1-Lateral surface

Provides origin to The muscles in the lateral compartment of the leg

2-Anterior surface

provides origin to the extensor muscles of the leg Extensor surface

3-Posterior surface

provides origin to some of the flexor muscles of the leg flexor surface

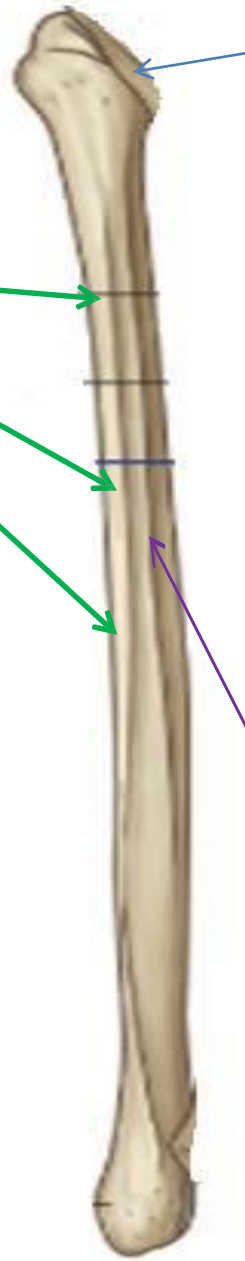

Interosseous border

Right fibula- anterior view

Dr. Shatarat, MD. PhD,
Department of Anatomy, School of Medicine The University of Jordan

Lower end of fibula

Inner surface

Malleolar fossa, located on the medial surface of the lateral malleolus

It is Inferior, Posterior and medial in the anatomical position
Therefore, it is commonly used to determine the side of the fibula (right or left)

Articular facet for talus

Malleolar fossa

Lower end of fibula

outer surface

Subcutaneous triangular area

Dr. Shatarat, MD. PhD,
Department of Anatomy, School of Medicine The University of Jordan

The common peroneal nerve is related to the neck of fibula

The common peroneal nerve in this area is covered by skin and fascia only therefore it is exposed to injuries

Foot drop

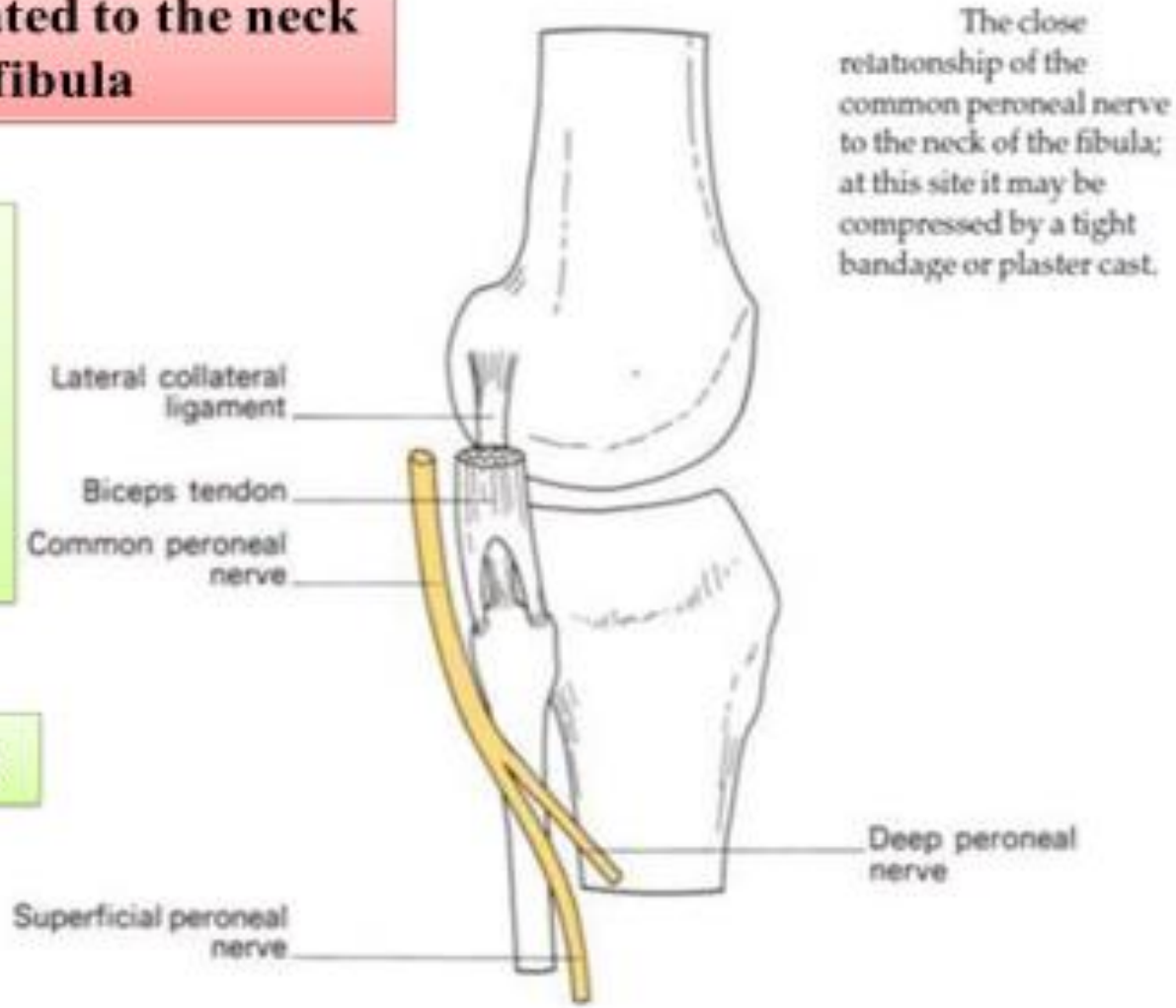

The close relationship of the common peroneal nerve to the neck of the fibula; at this site it may be compressed by a tight bandage or plaster cast.

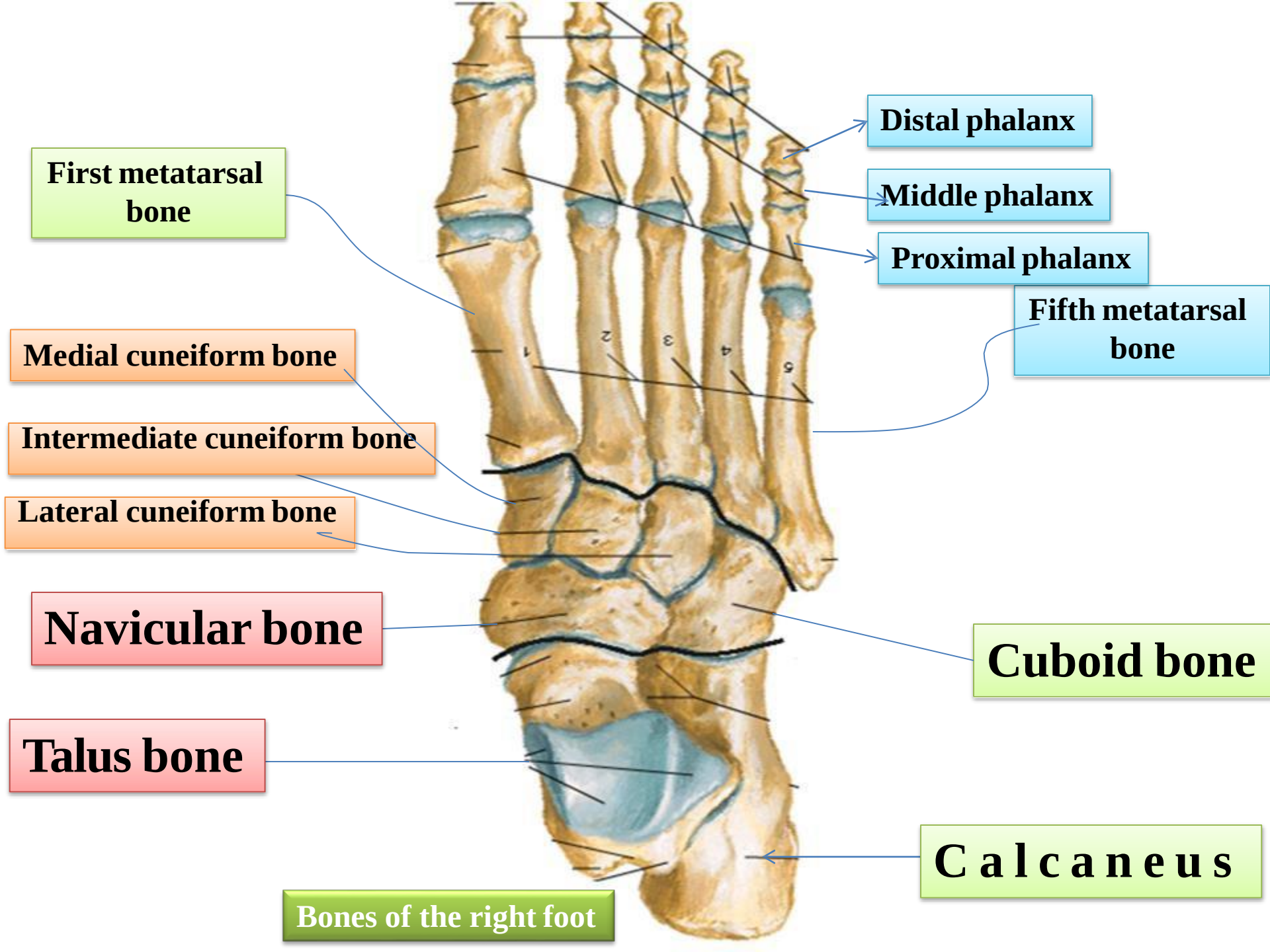
Distal phalanx
Middle phalanx
Proximal phalanx
Fifth metatarsal bone
First metatarsal bone
Medial cuneiform bone
Intermediate cuneiform bone
Lateral cuneiform bone
Navicular bone
Cuboid bone
Talus bone
C a l c a n e u s
Bones of the right foot

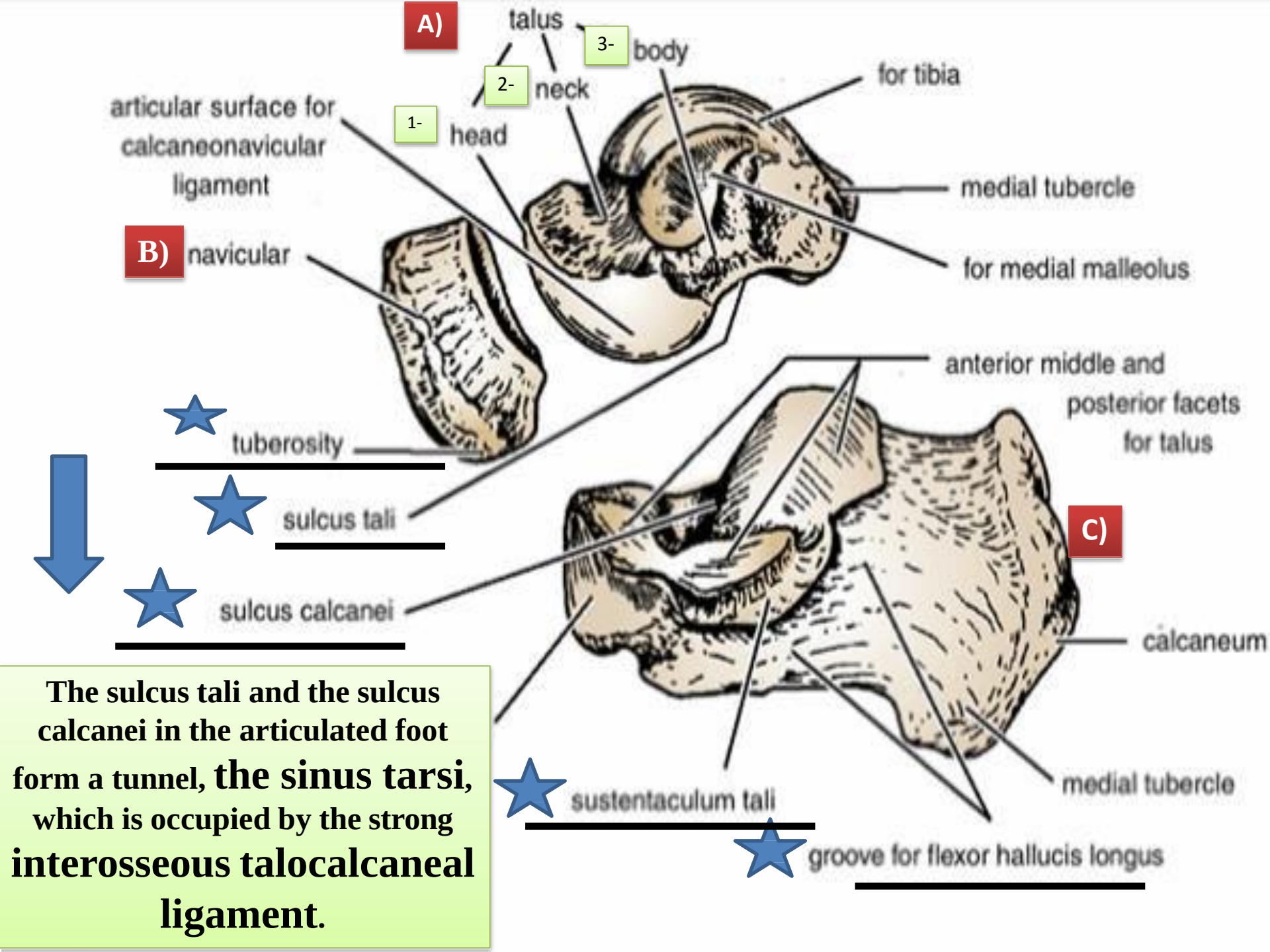

The sulcus tali and the sulcus calcanei in the articulated foot form a tunnel, the sinus tarsi, which is occupied by the strong interosseous talocalcaneal ligament.

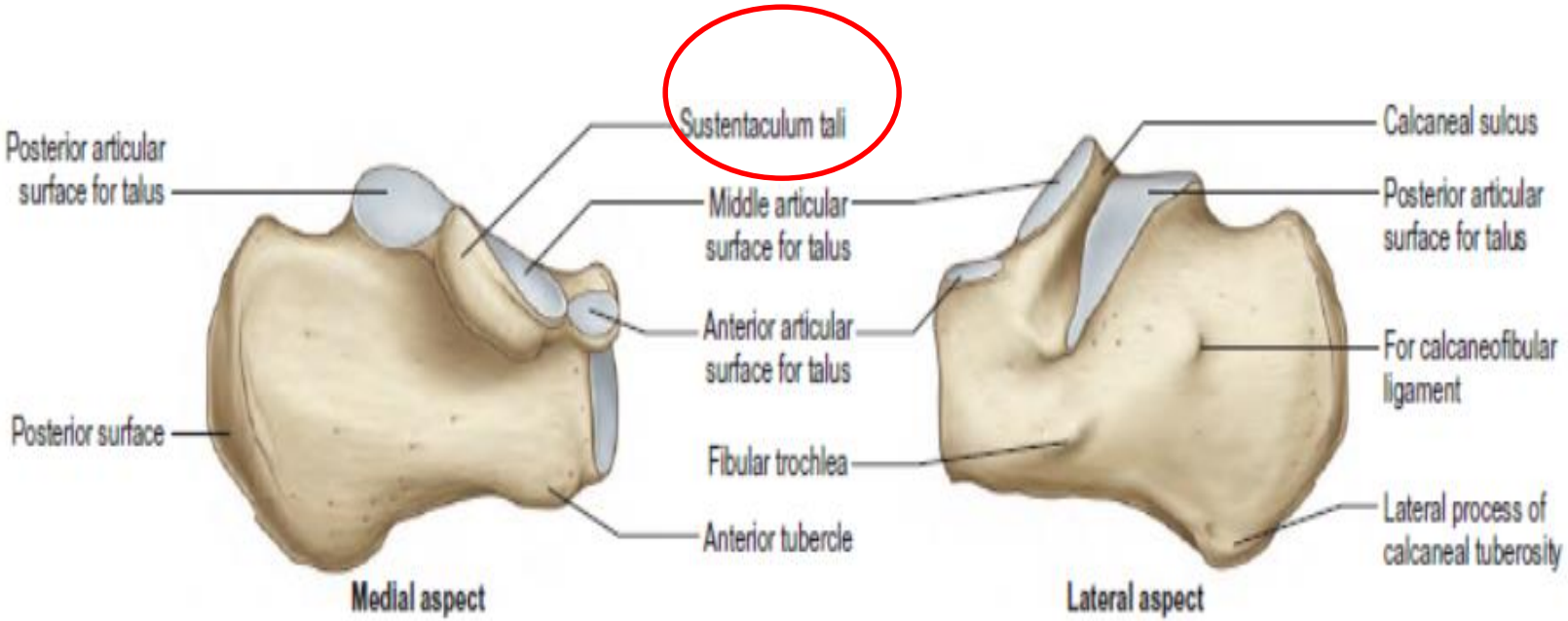
Posterior articular surface for talus
Sustentaculum tali
Middle articular surface for talus
Anterior articular surface for talus
Posterior surface
Fibular trochlea
Anterior tubercle
Medial aspect
Calcaneal sulcus
Posterior articular surface for talus
For calcaneofibular ligament
Lateral process of calcaneal tuberosity
Lateral aspect

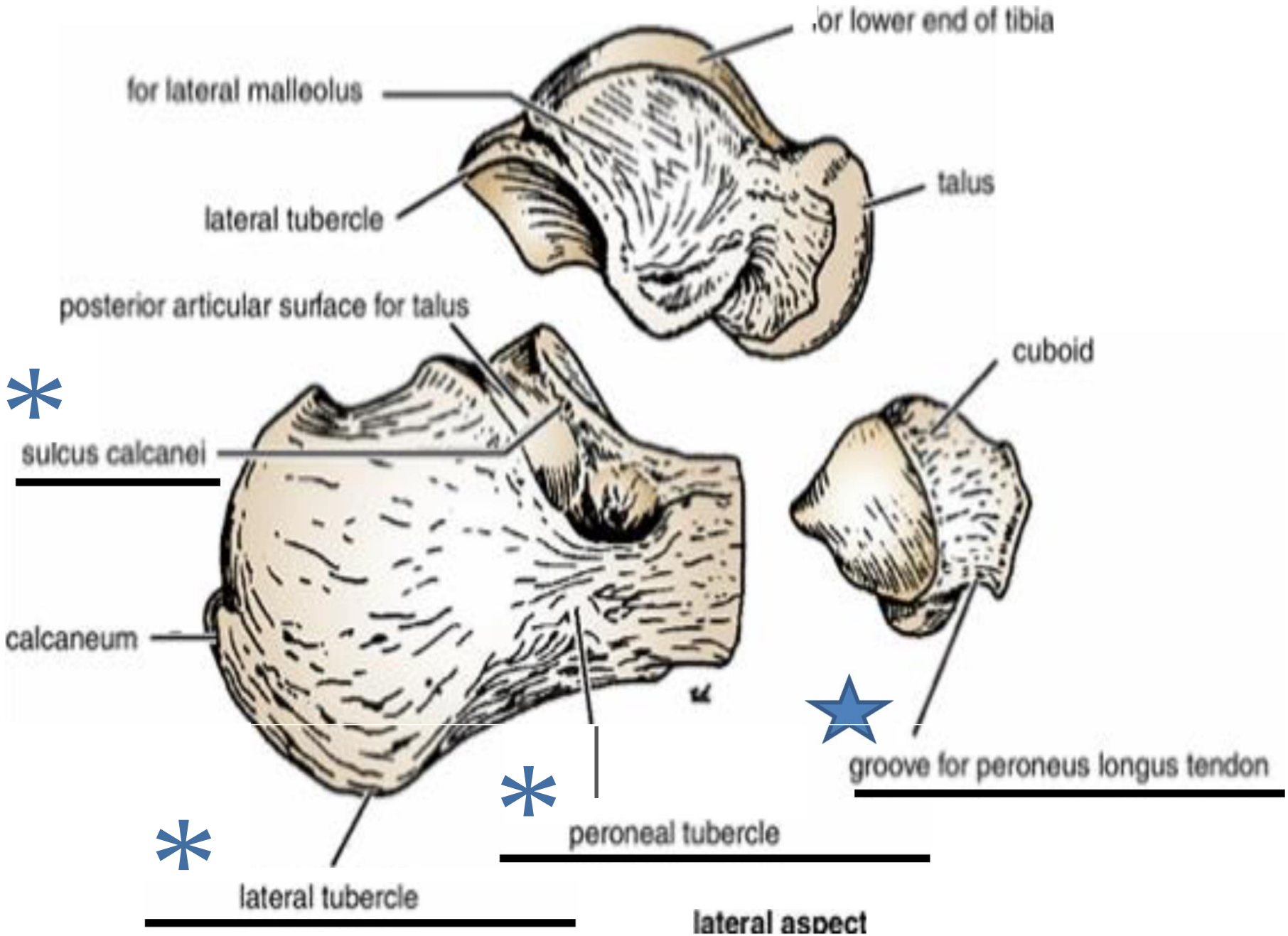
for lower end of tibia
for lateral malleolus
talus
lateral tubercle
posterior articular surface for talus
cuboid
sulcus calcanei
calcaneum
groove for peroneus longus tendon
peroneal tubercle
lateral tubercle
lateral aspect

Bones of Foot

Dorsal View

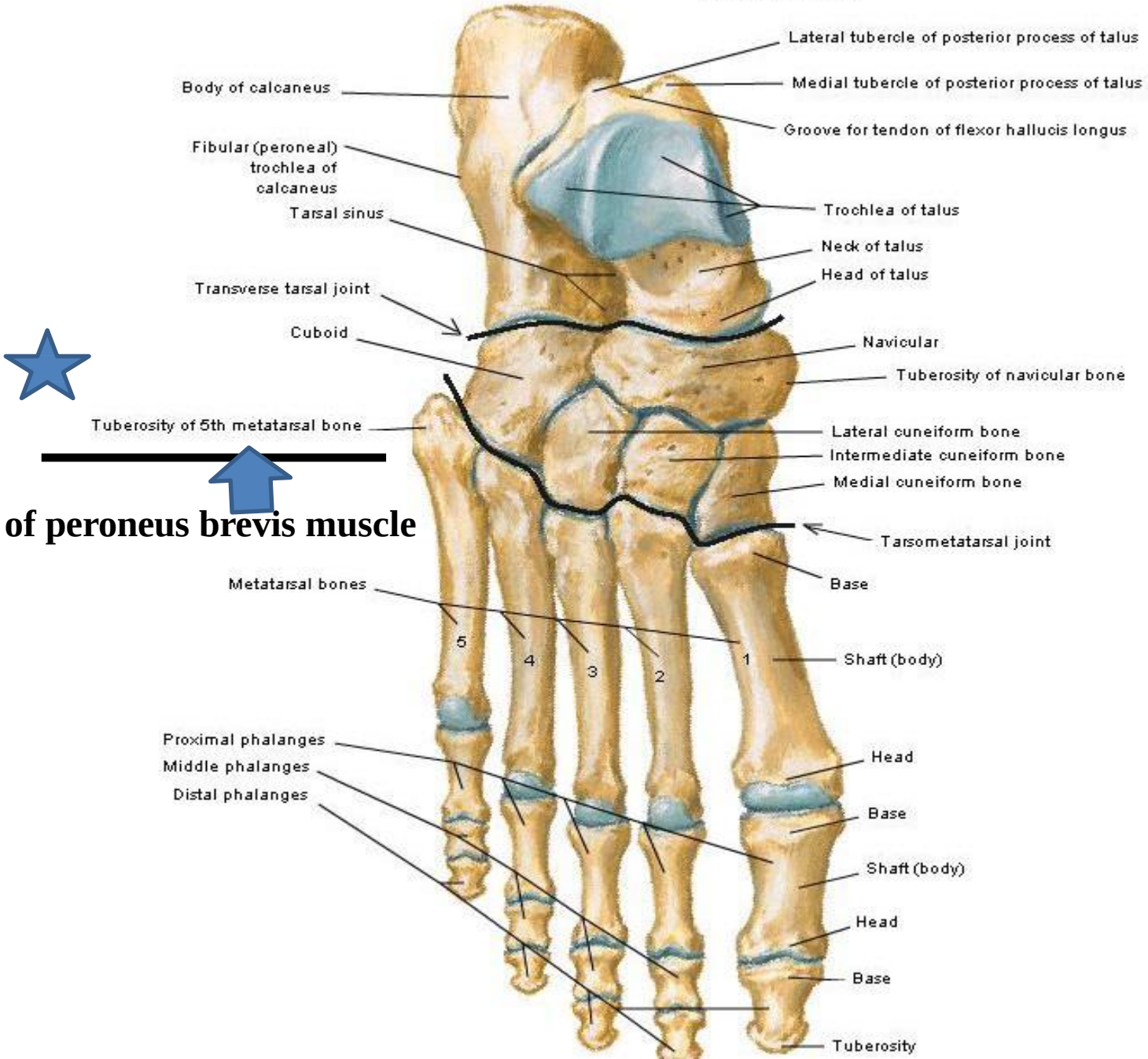

nsertion of peroneus brevis muscle

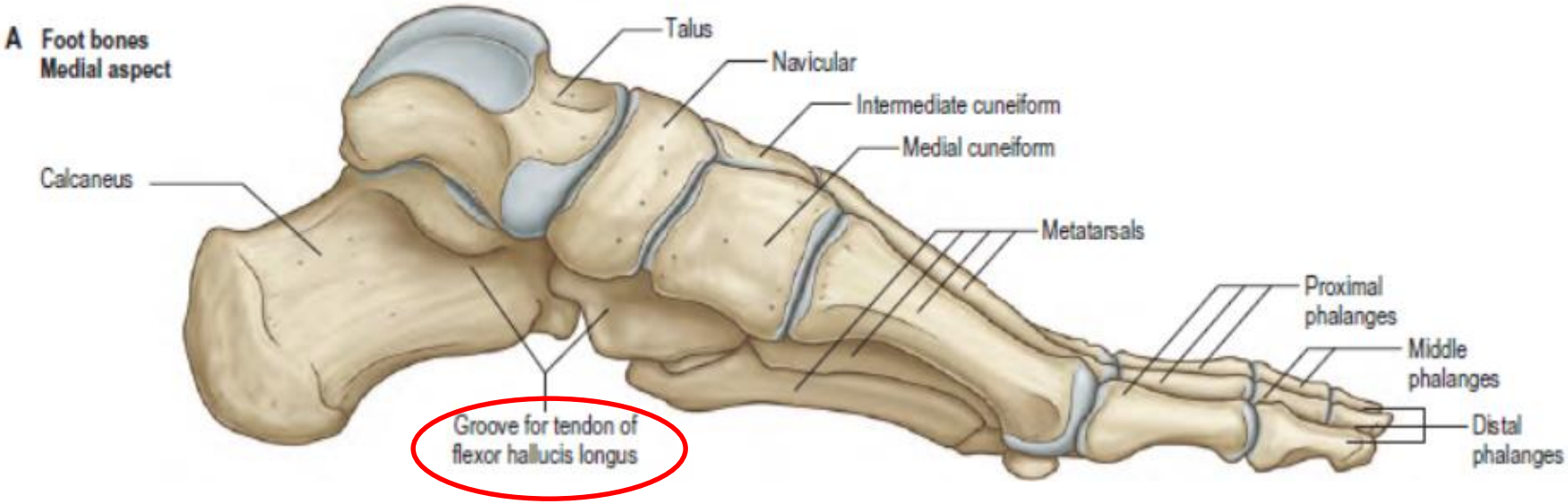

Dr. Shatarat, MD. PhD,
Department of Anatomy, School of Medicine The University of Jordan

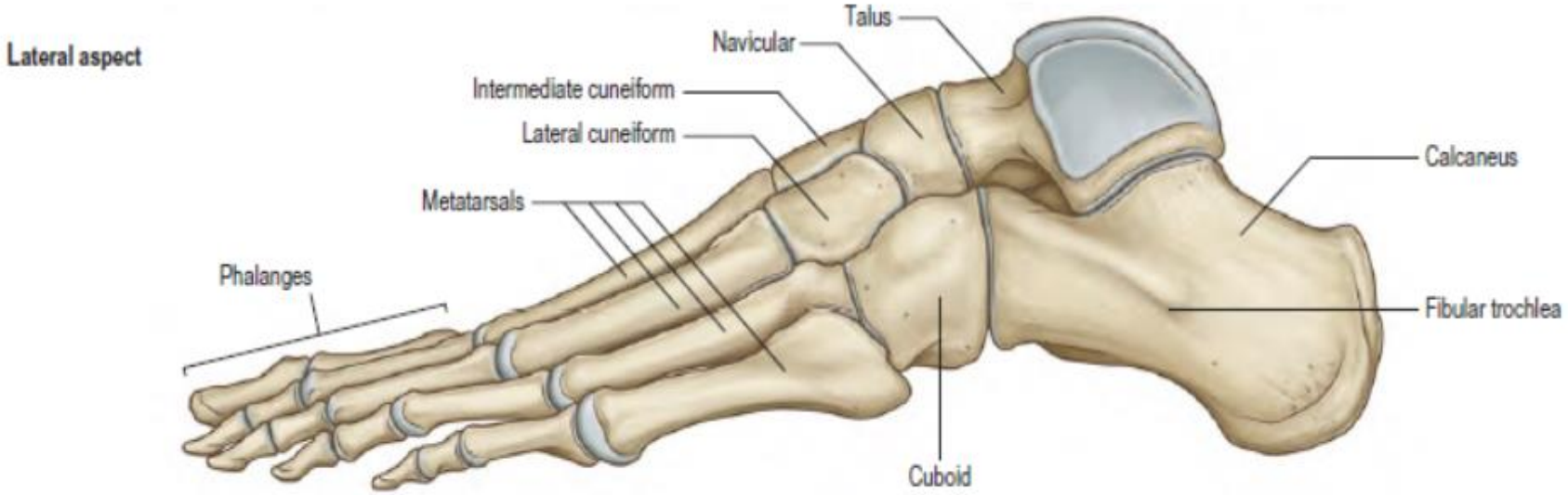

Dr. Shatarat, MD. PhD,
Department of Anatomy, School of Medicine The University of Jordan