DERIVATIVES OF THE MESODERMAL GERM LAYER

Paraxial mesoderm

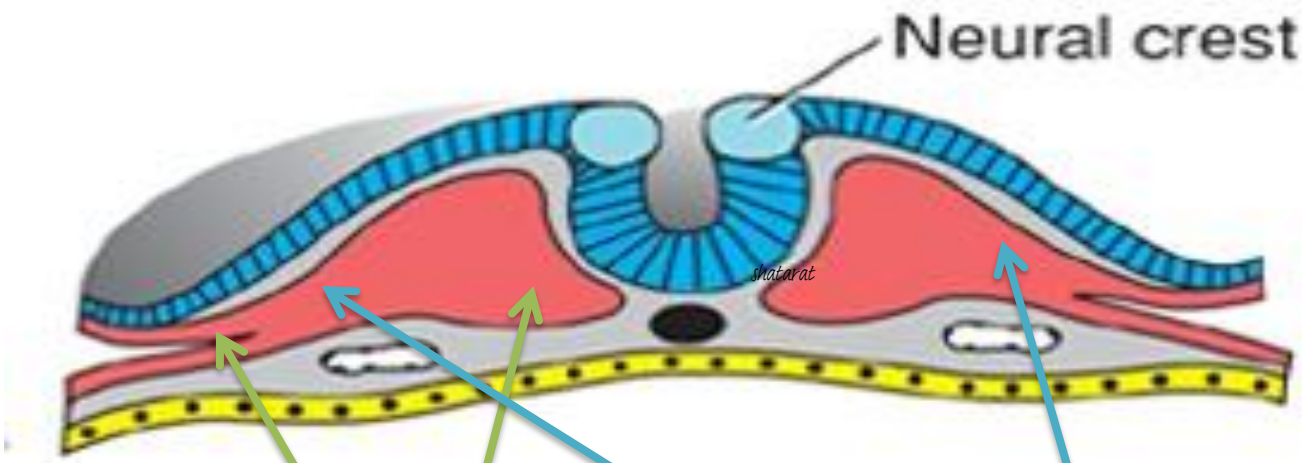

It develops into
TWO PERIPHERAL MASSES
and **a constriction in the middle**

Called:

1-Medail mesoderm

2-Intermediate mesoderm

3-lateral mesoderm

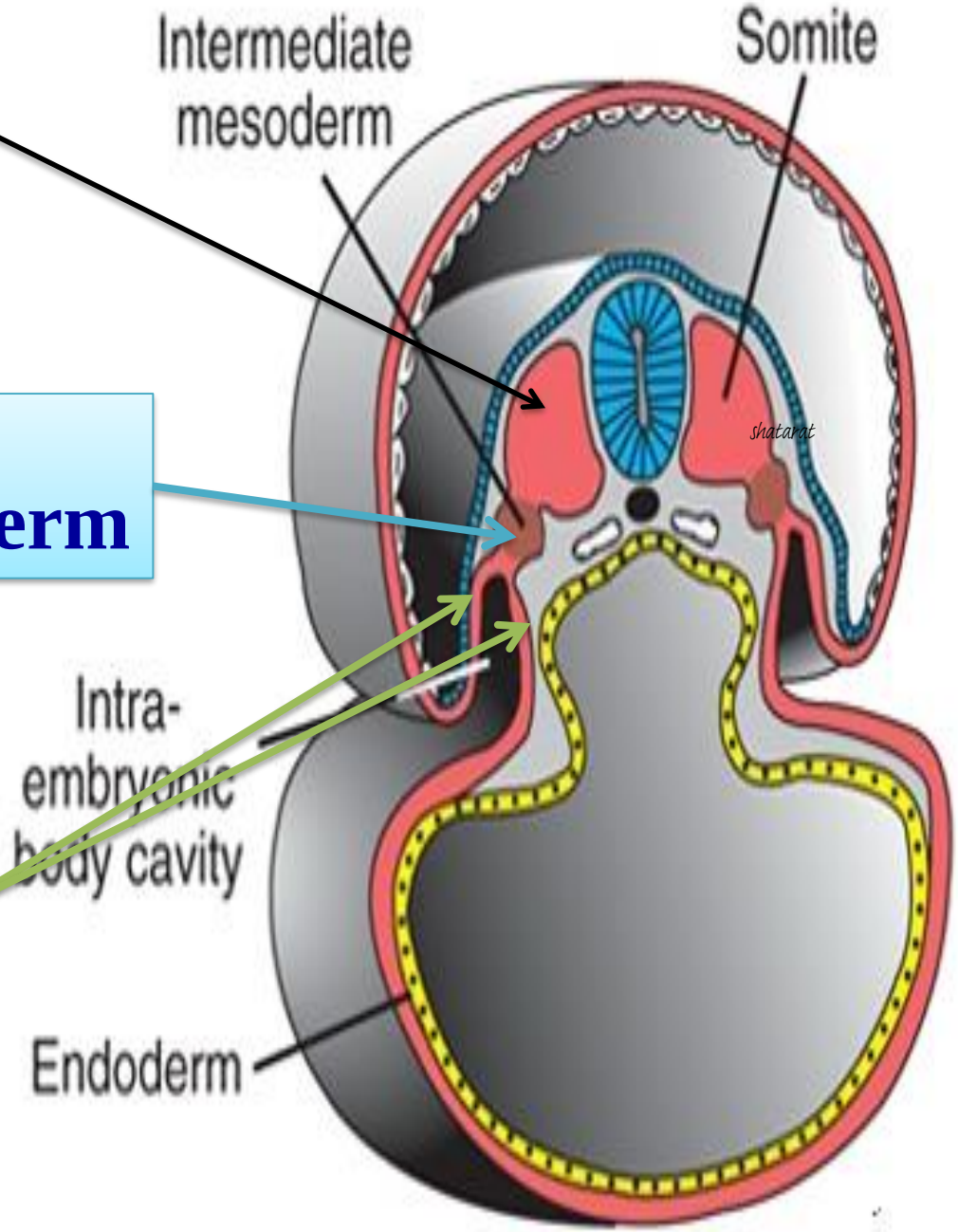

Medial mesoderm

•The medial mesoderm enlarges pushing the ectoderm upwards to give the **somites**

➢As the embryo develops the number of the somites Increases from one to reach about 44-45 somites

➢ when the embryo is completely developed

About 10 somites vanish when the tail of the embryo is lost

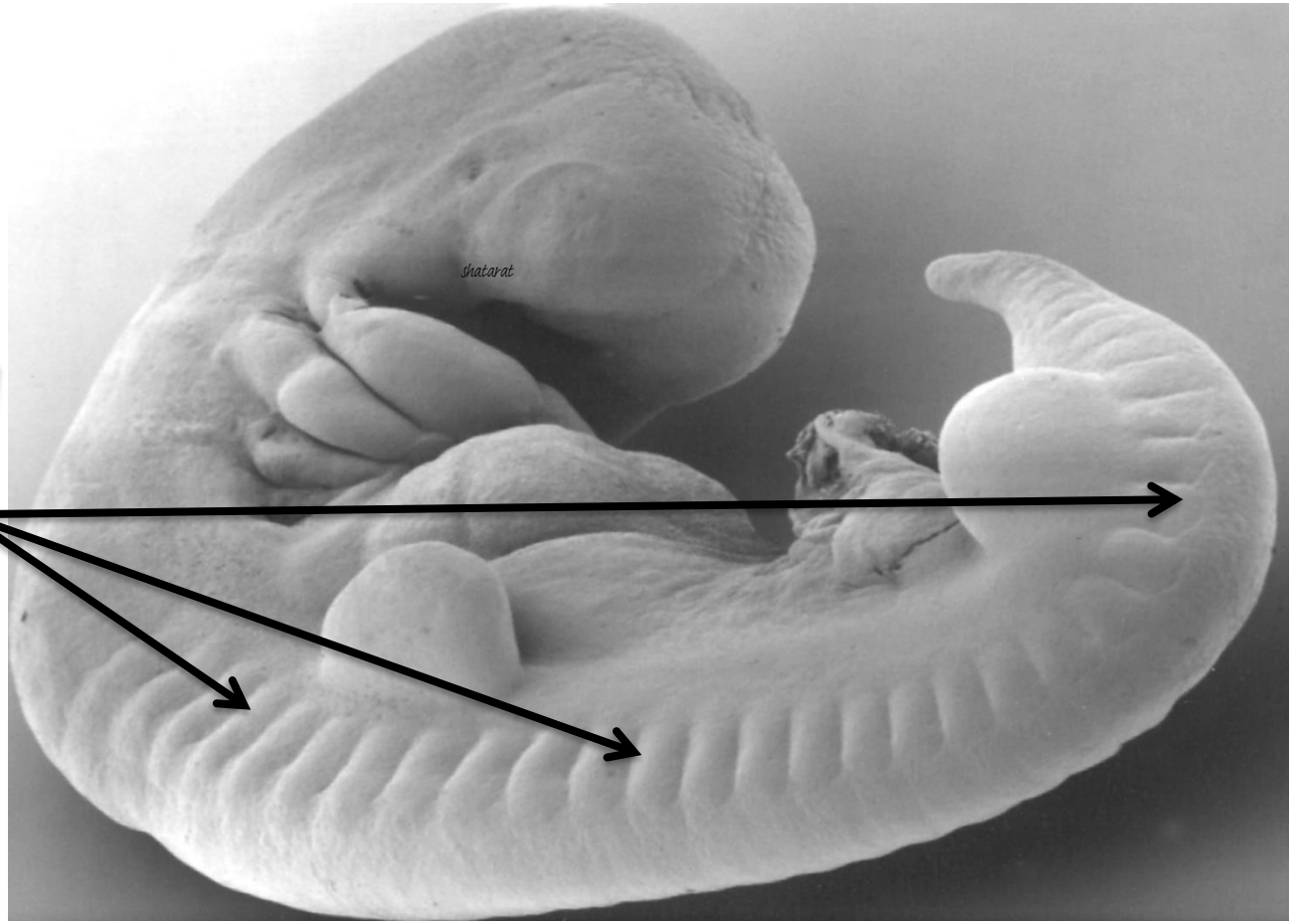

❖**The first pair** of somites arises in the **occipital region** of the embryo at approximately the 20th day of development

❖From here, new somites appear in craniocaudal sequence at a rate of approximately three pairs per day until the end ***of the fifth week***,

There are:

four occipital
eight cervical
12 thoracic
five lumbar
five sacral,
and eight to 10 coccygeal pairs.

The
first occipital and the last five to seven coccygeal somites later disappear

WHAT IS THE destiny OF EACH SOMITE?

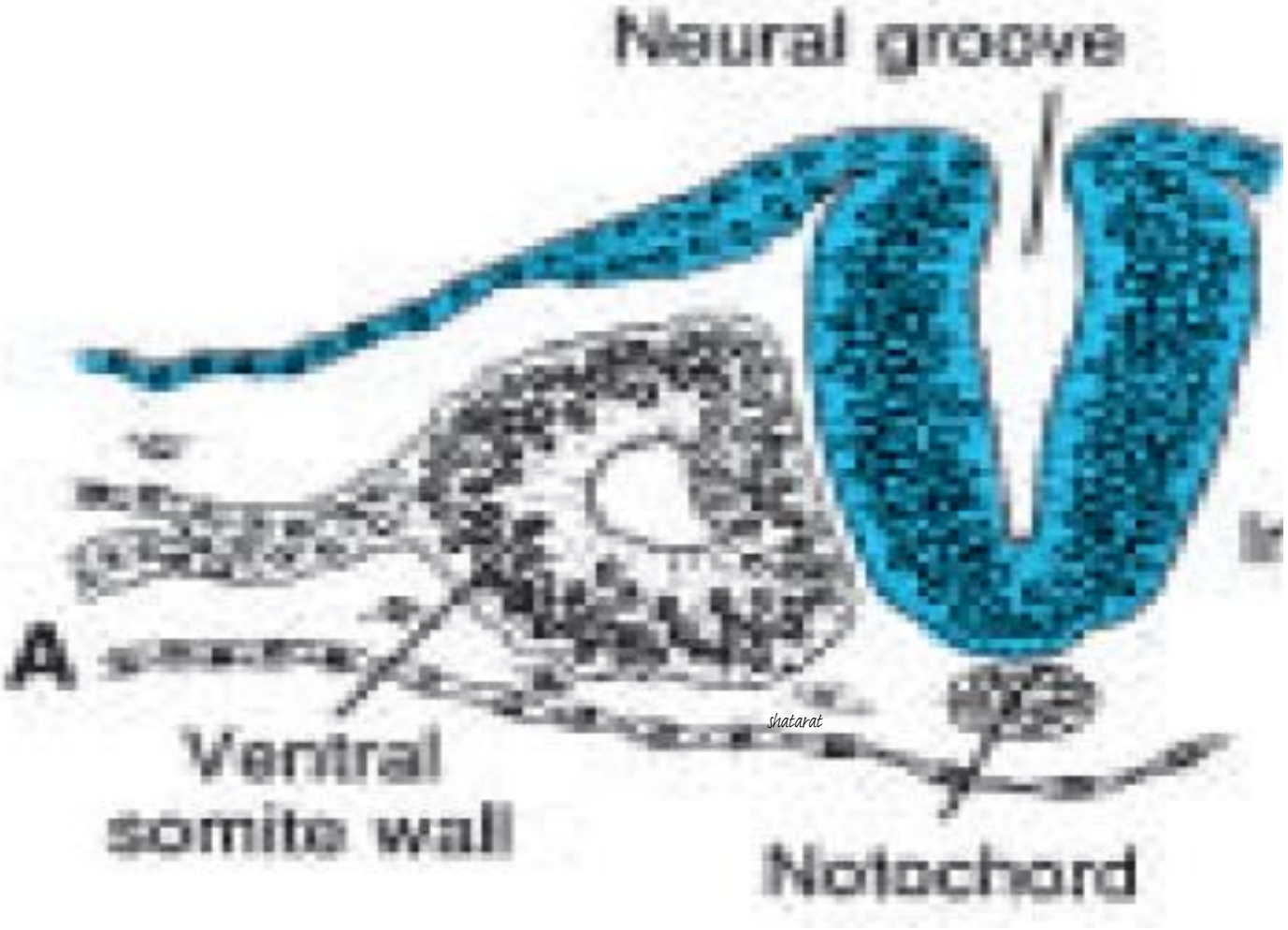

By the beginning of the fourth week
cells forming the ***<u>ventral and medial walls of the somite</u>***
lose their compact organization,
and shift their position to surround the notochord
These cells, collectively known as

THE SCLEROTOME

They will surround the spinal cord and notochord to form

the vertebral column

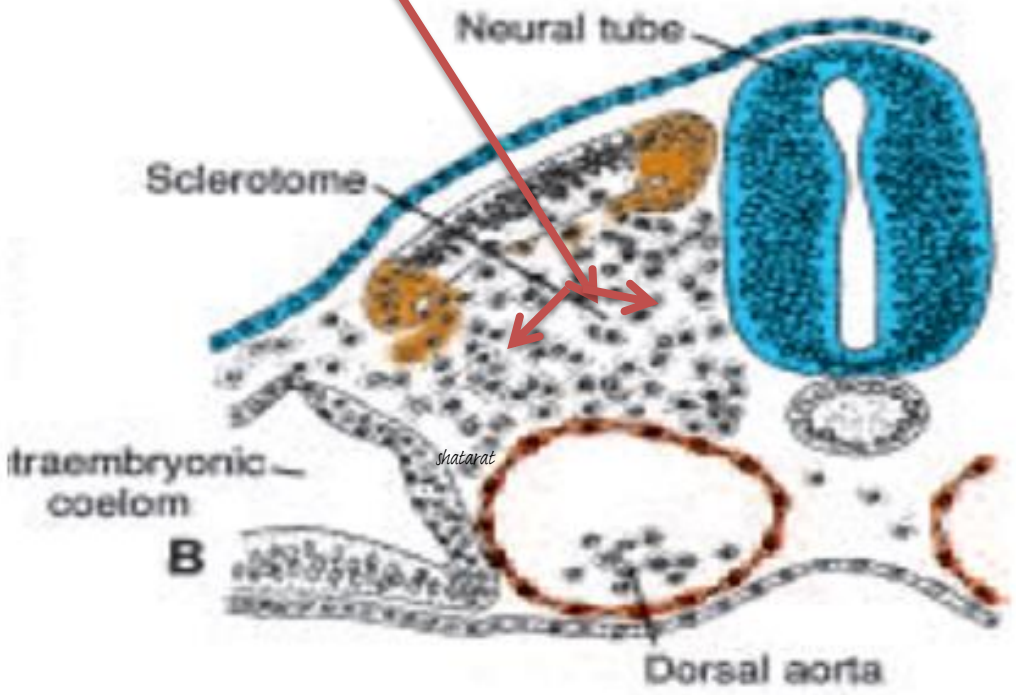

Cells at the dorsolateral portion of the somite also migrate as precursors of the

limb and body wall

shatarat

musculature

(hypomeric) musculature

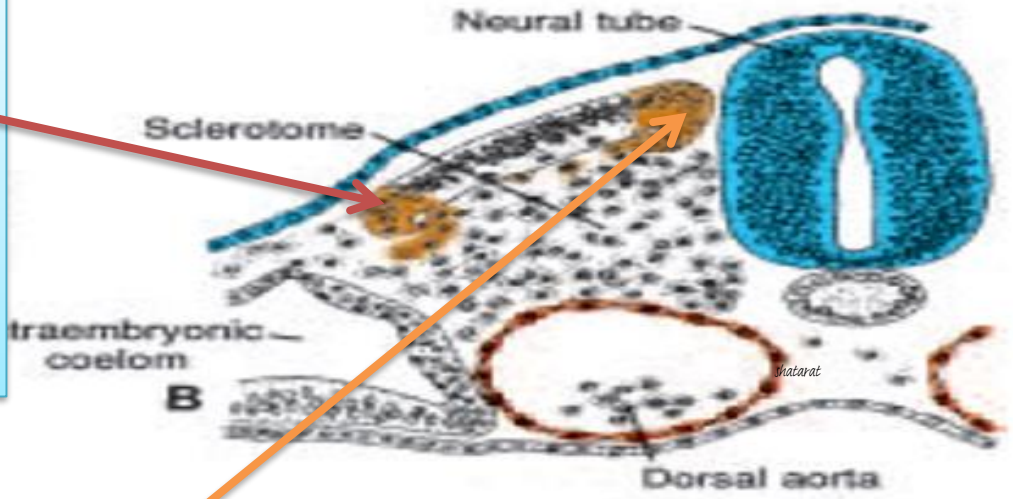

After migration of these muscle cells and cells of the sclerotome,

Cells at the dorsomedial portion of the somite proliferate and migrate to form a new layer

THE MYOTOME

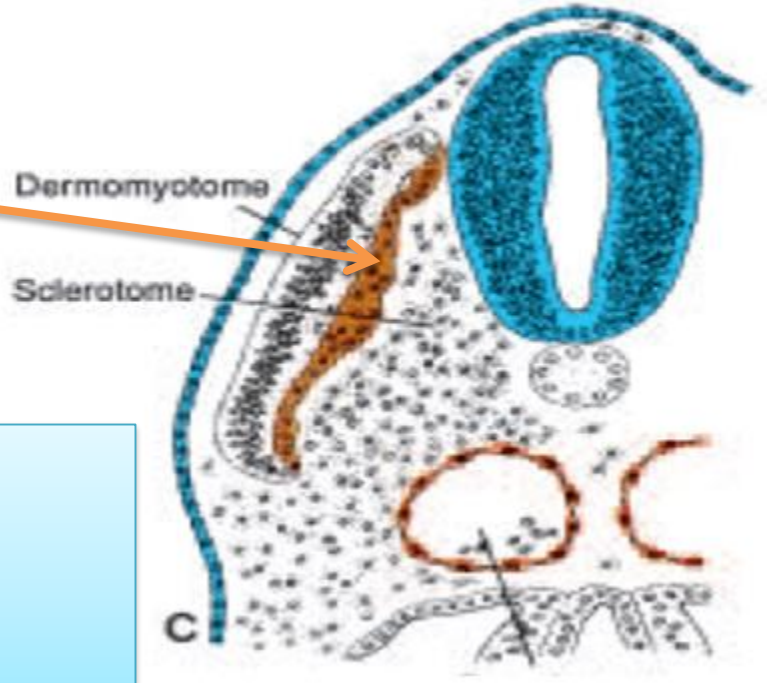

myotome contributes to muscles of the back (epaxial musculature)

or epimeric musculature

the **extensor muscles of the vertebral** column

The remaining dorsal epithelium
forms the dermatome

dermatomes form
the dermis and subcutaneous tissue of the skin

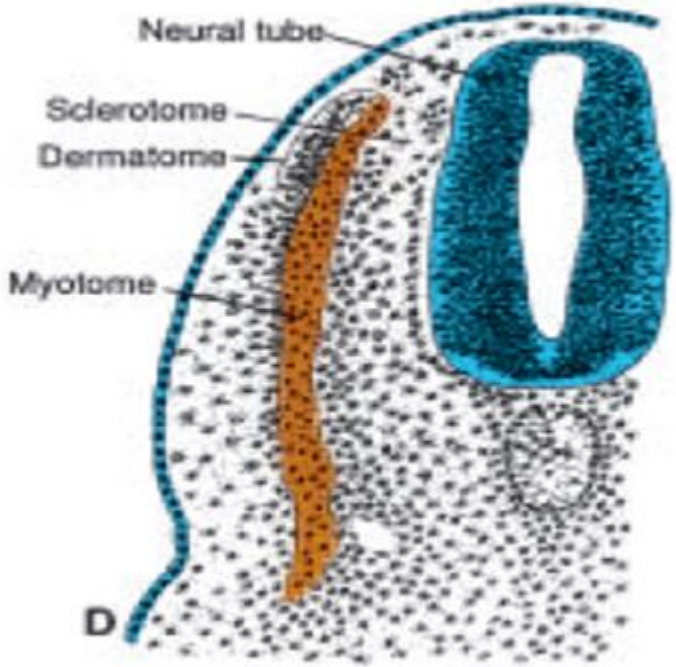

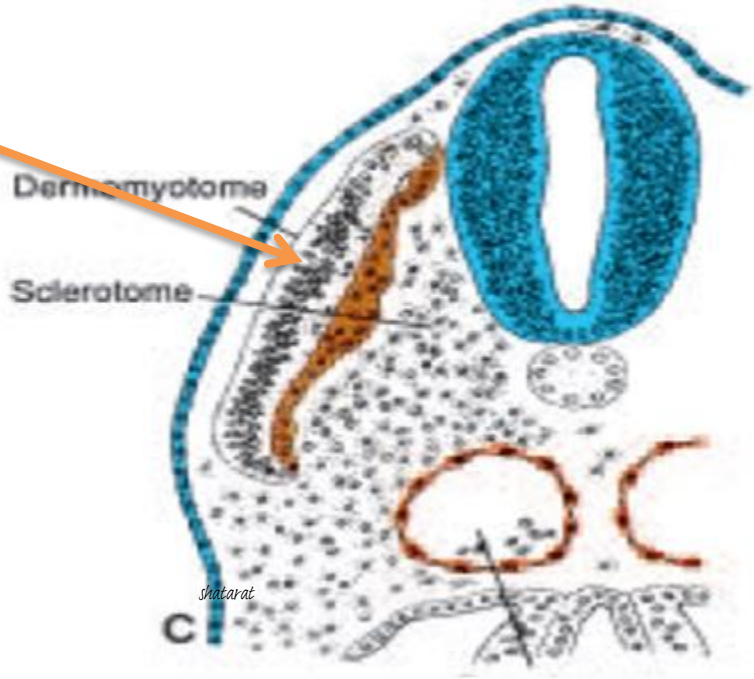

DERIVATIVES OF THE INTERMEDIATE MESODERM

It gives off:

1- Urine performing tubule (Kidney and ureter)

2-internal genitalia in males and femals (part of it not all)

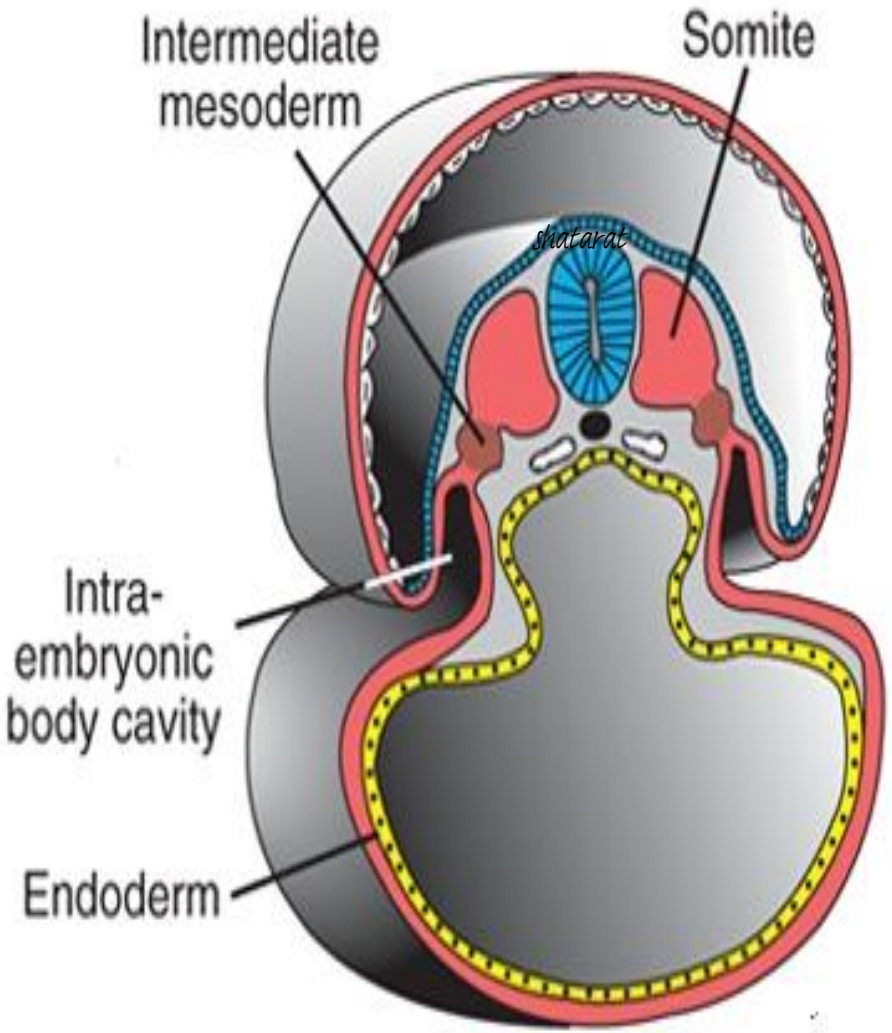

Embryonic folds

WHY the embryo folds?

1- Extensive and rapid growth of the cranial end of the neural tube

2- The faster growth of the axial part of the embryonic disc than its periphery

3- Enlargement of the amnion

Folding of the embryo
Cephalocaudally and Laterally

Head (cephalic) fold

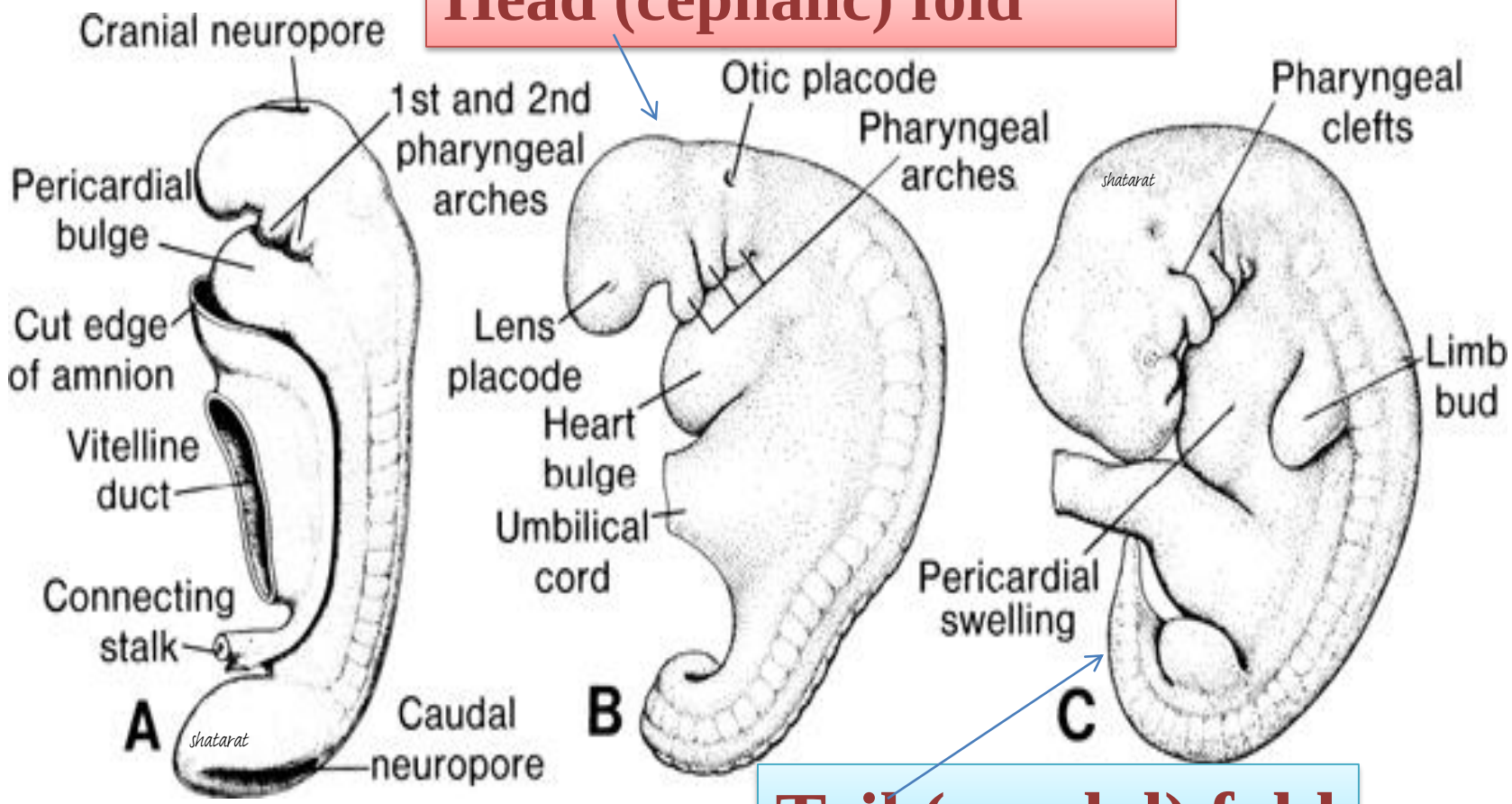

Tail (caudal) fold

The embryonic disc begins to bulge into the amniotic cavity and to fold

Cephalocaudally

Folding of the embryo
Cephalocaudally

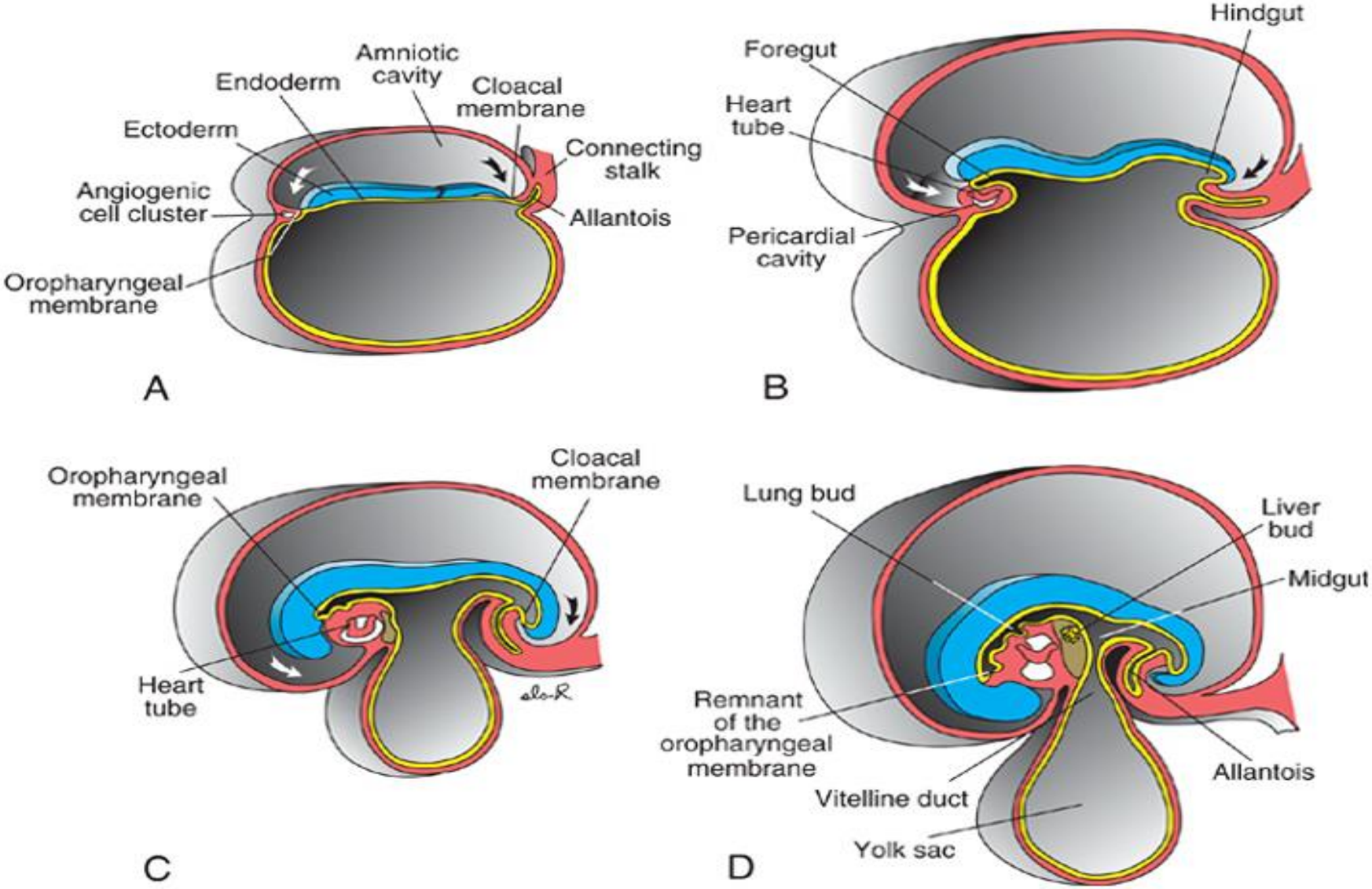

Copyright © 2010 Wolters Kluwer Health | Lippincott Williams & Wilkins

Folding of the embryo Laterally

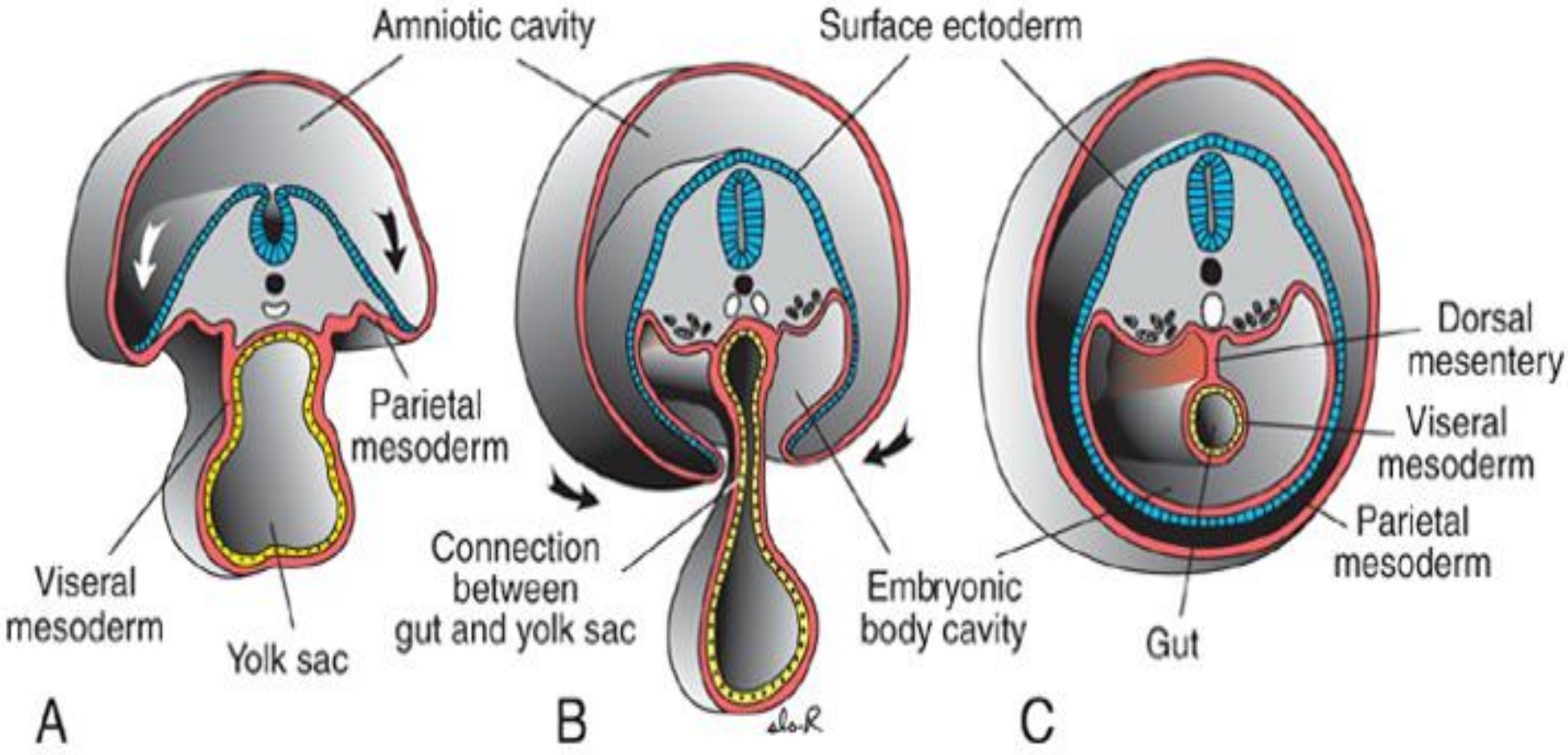

Copyright © 2010 Wolters Kluwer Health | Lippincott Williams & Wilkins

DERIVATIVES OF THE LATERAL MESODERM

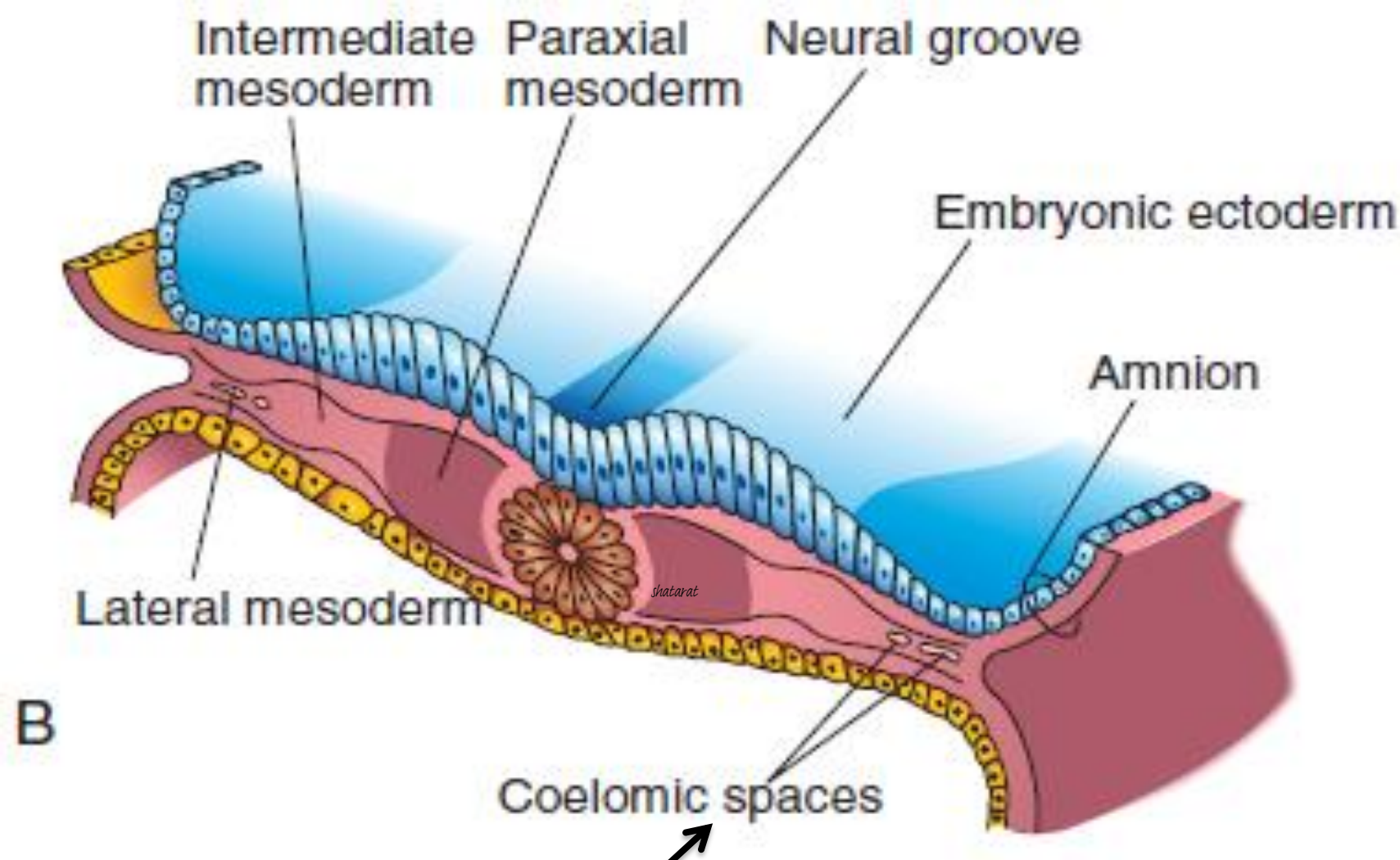

The intraembryonic coelom (body cavity) first appears as small, isolated, **coelomic spaces in the lateral intraembryonic** mesoderm

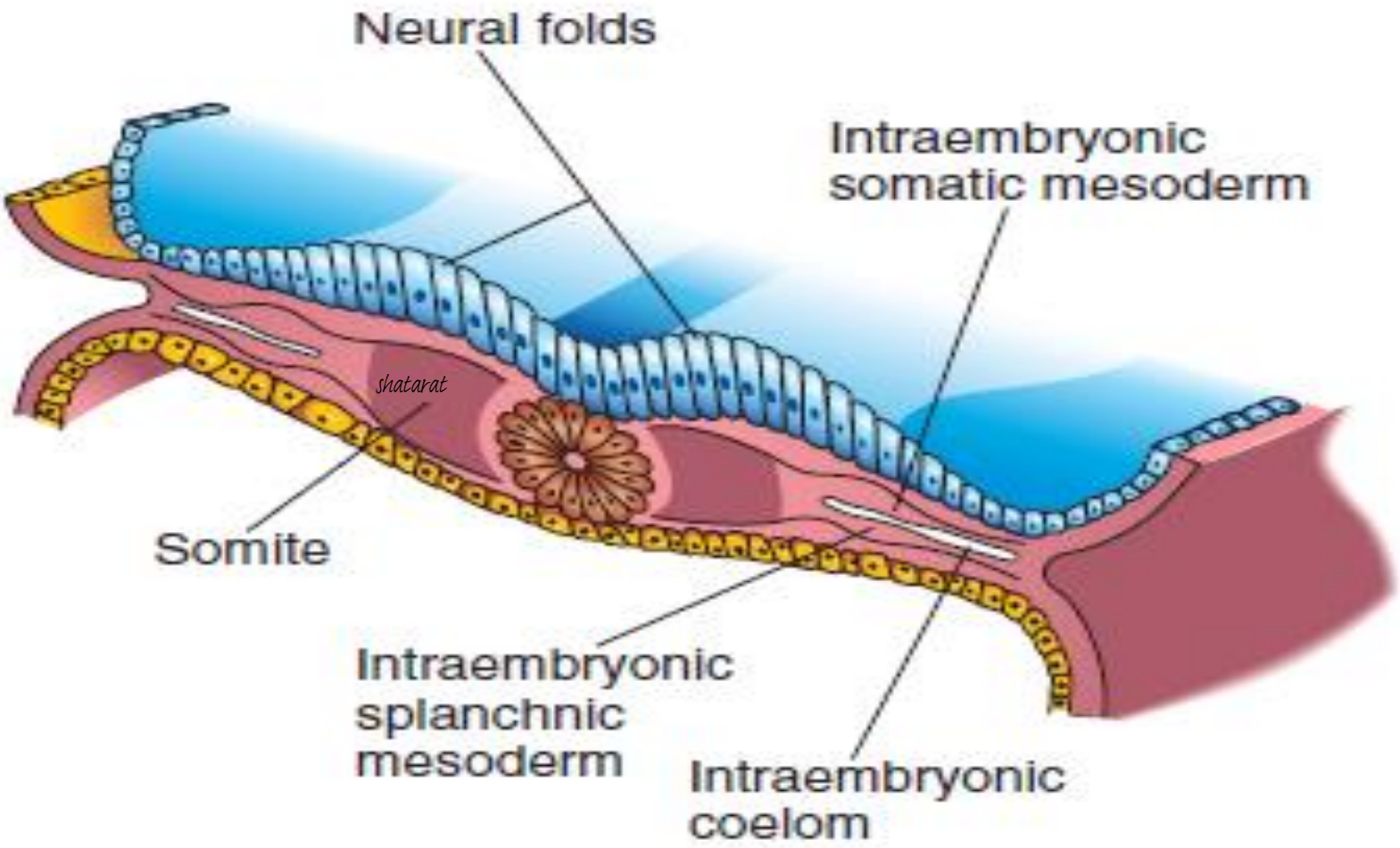

These spaces coalesce to form
a single, horseshoe-shaped cavity—
the **intraembryonic**
coelom

The coelom divides the
lateral mesoderm into two layers:

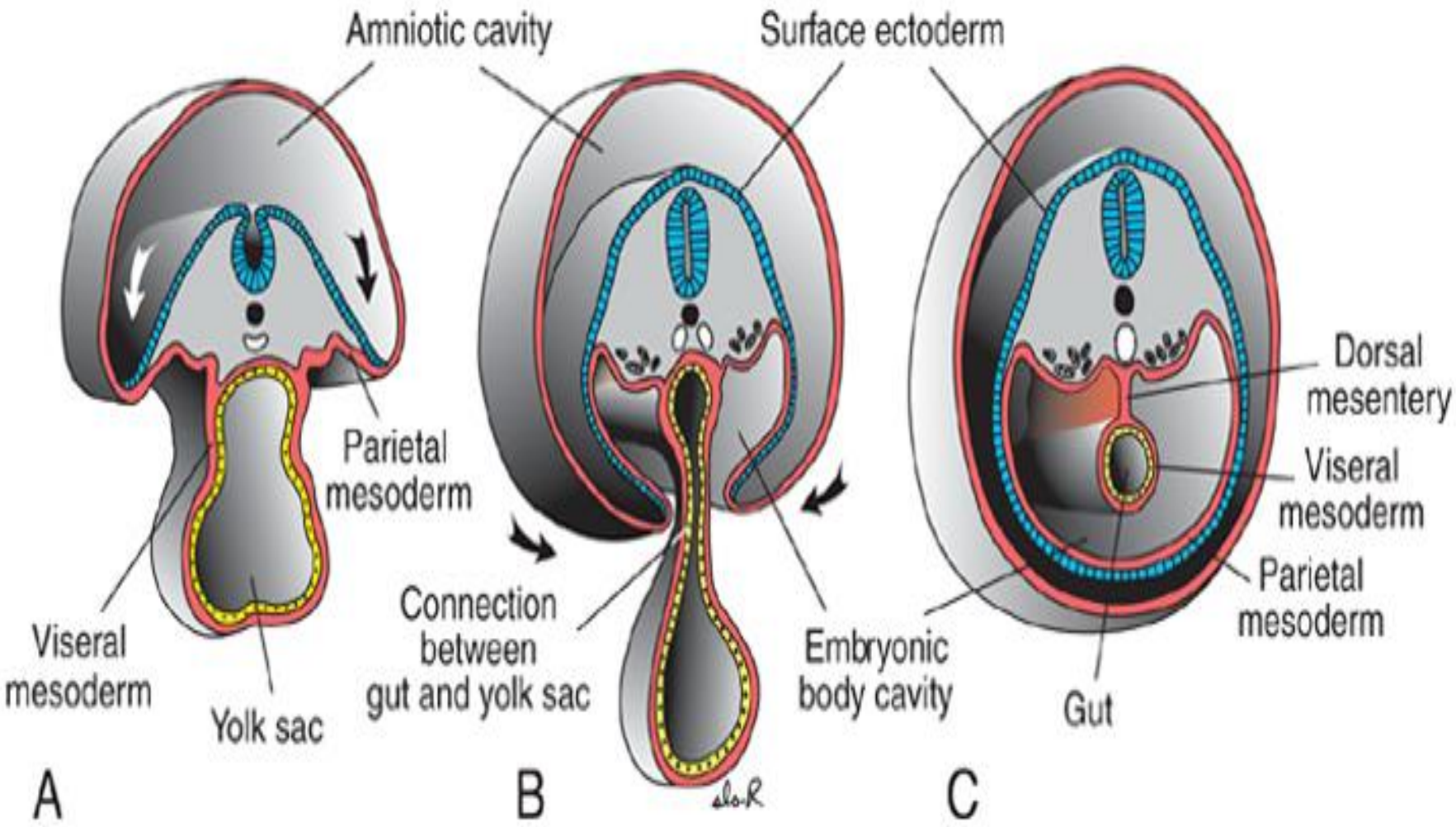

Copyright © 2010 Wolters Kluwer Health | Lippincott Williams & Wilkins

Lateral mesoderm splits into two layers:

1- **Parietal (somatic)**

2- **Visceral (splanchnic)**

- Mesoderm from **the parietal layer**, together with **overlying ectoderm**, forms **the lateral body wall folds**
- These folds, together with the head (cephalic) and tail (caudal) folds, **close the ventral body wall**

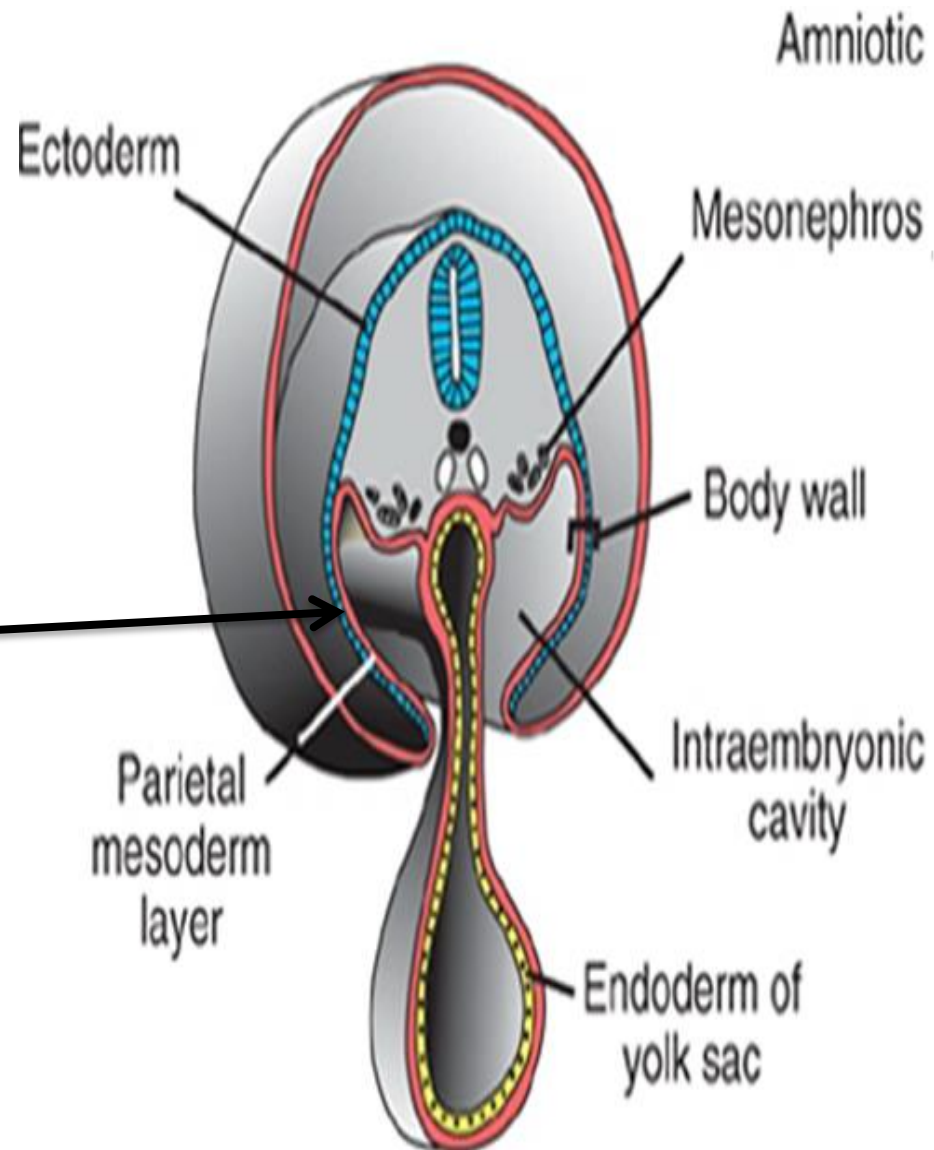

The visceral layer of lateral mesoderm

Surrounds the primitive gut and **together with embryonic endoderm, forms**

THE WALL OF THE GUT TUBE

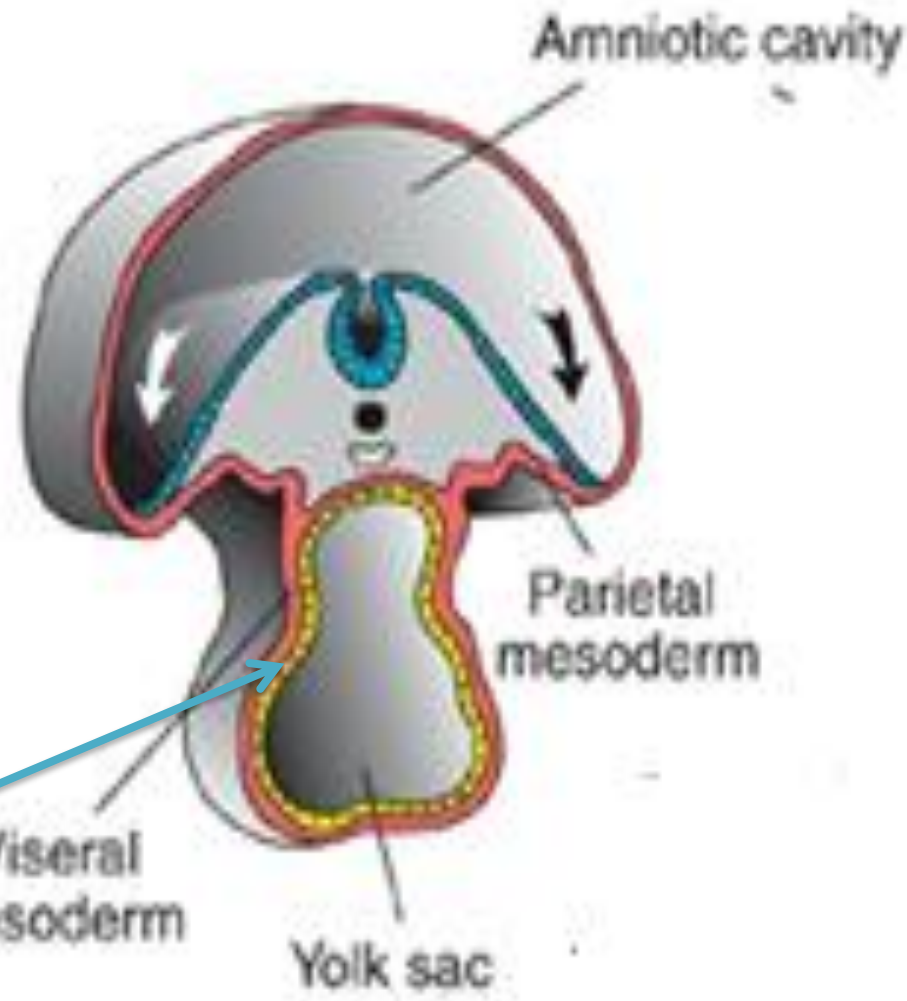

DERIVATIVES OF THE ENDODERMAL GERM LAYER

➢**The gastrointestinal tract is the main organ system derived from the endodermal germ layer**

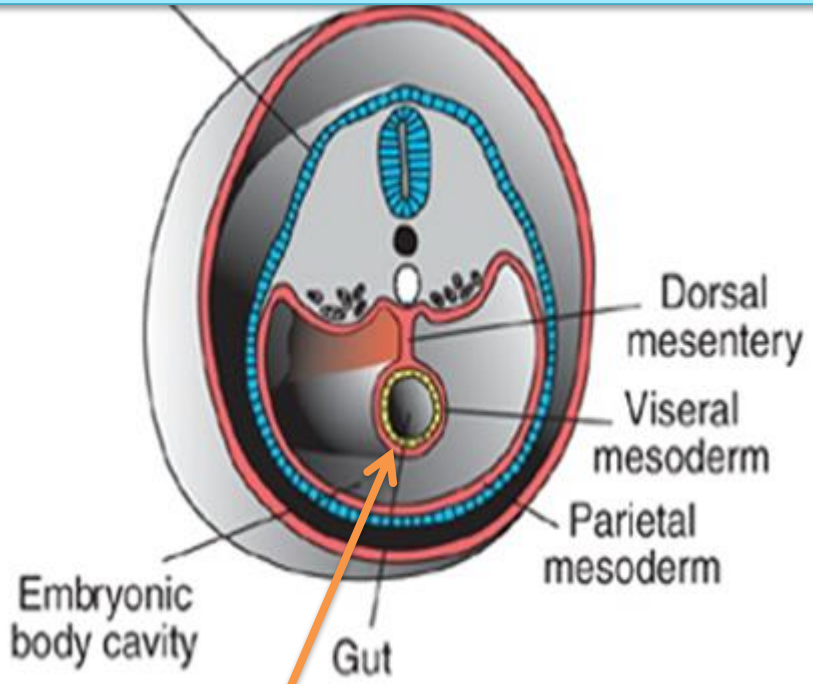

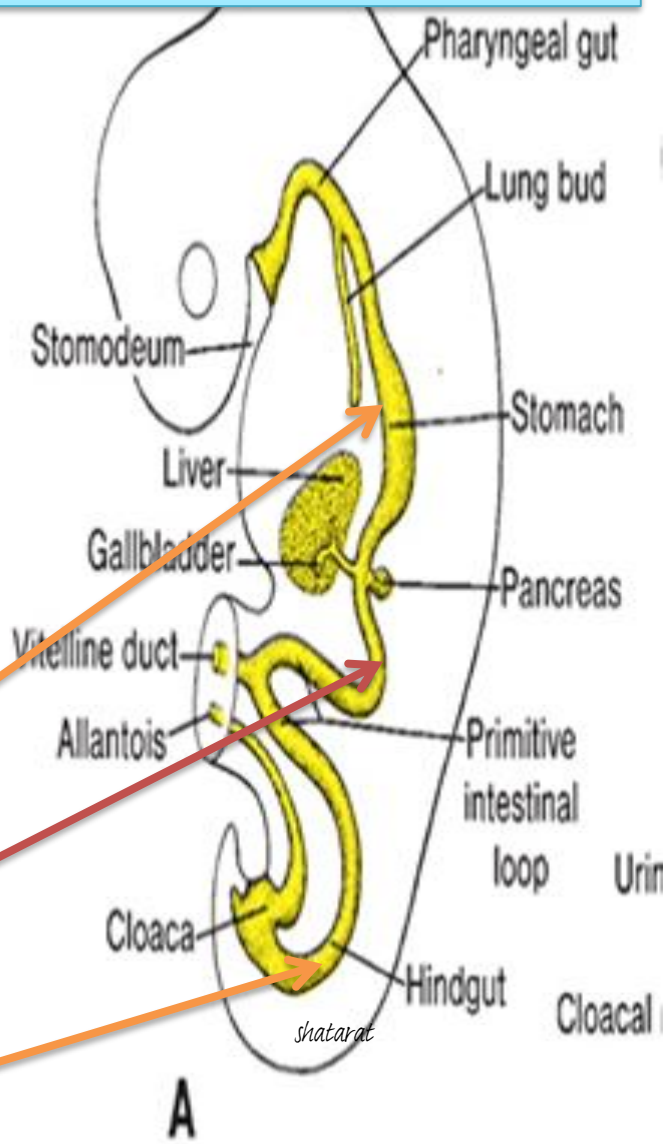

The tube is divided into three regions:

FOREGUT

MIDGUT

HINDGUT

<u>The midgut remains in communication with the yolk sac</u>.
Initially, this connection is wide but as a result of body folding, it gradually becomes long and narrow to form

<u>the vitelline duct</u>

Only much later, when the vitelline duct is obliterated, does the midgut lose its connection with the original endoderm-lined cavity and obtain its free position in the abdominal cavity

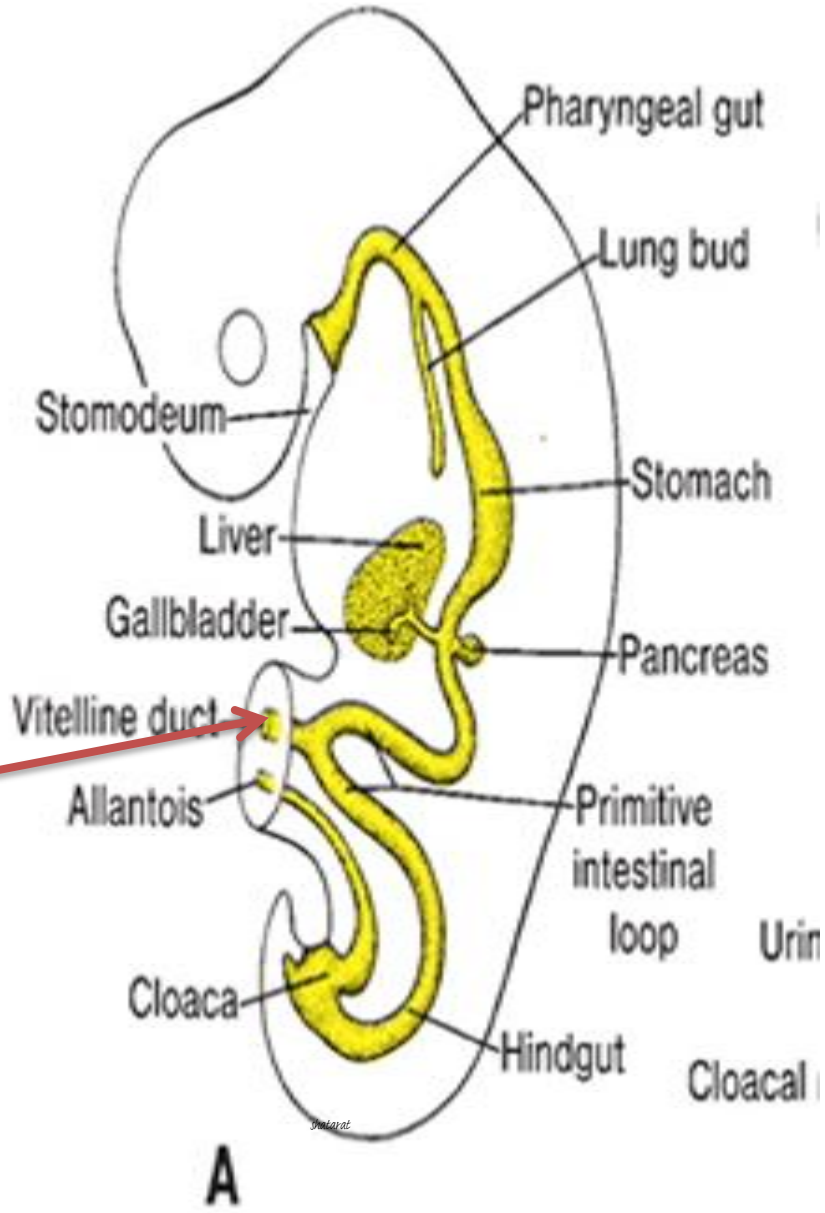

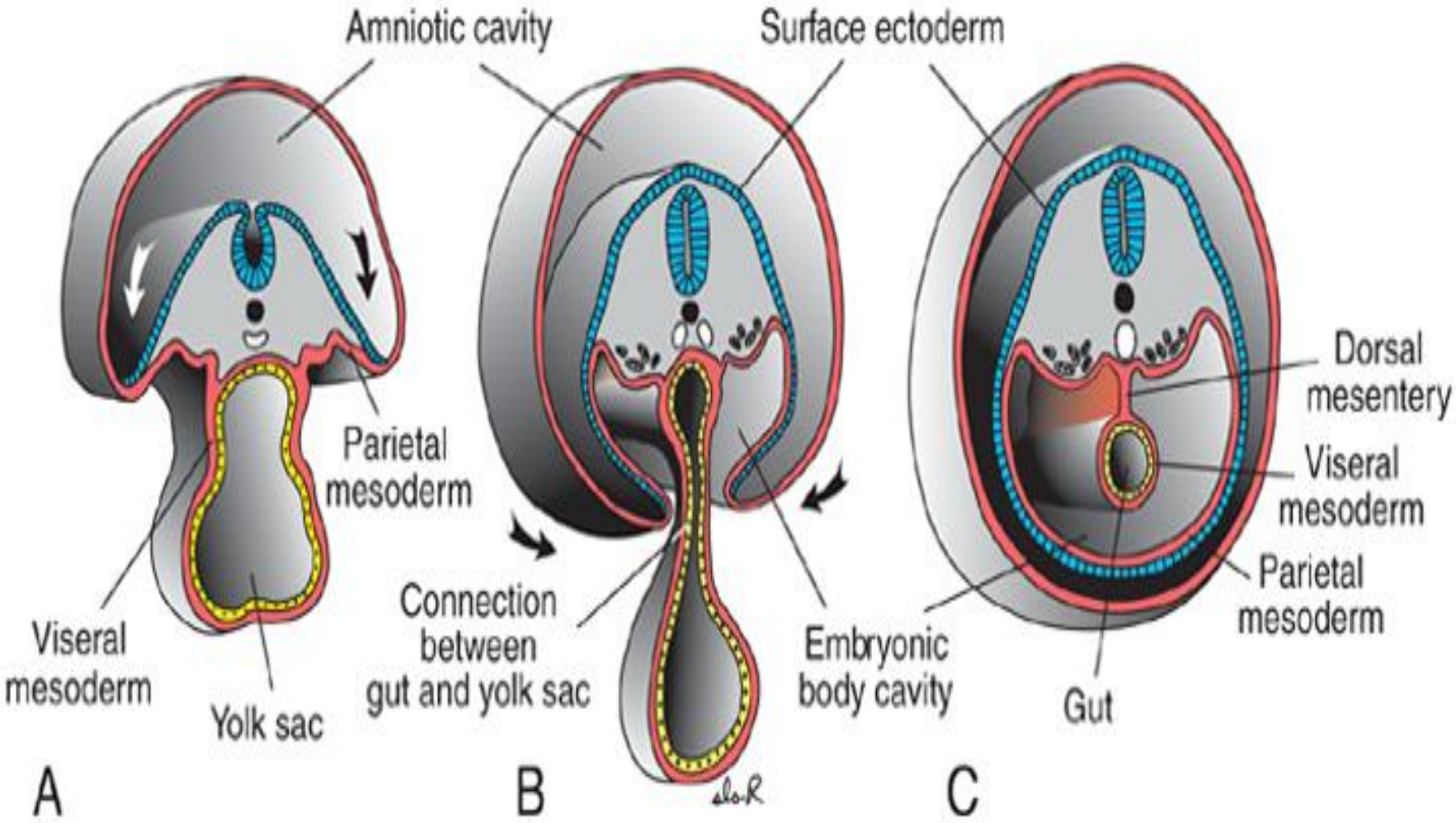

Copyright © 2010 Wolters Kluwer Health | Lippincott Williams & Wilkins