Slides of Anatomy

Please note: These slides were Made by the Premed Academic Team to fit the slides of spring 2019.

ABDOMEN

Lecture 2

Esophagus

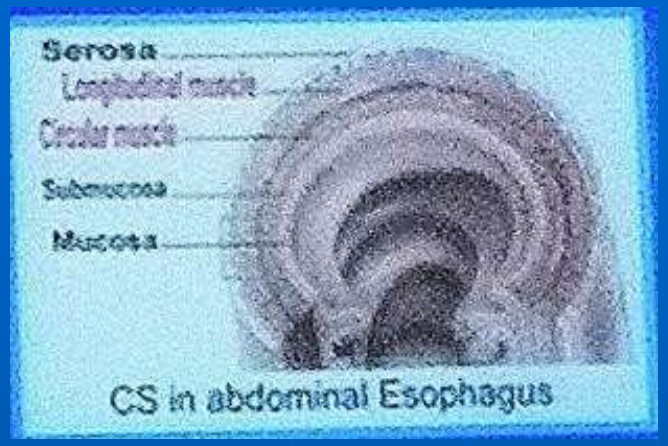

- About 25 cm long.
- Extends from lower end of pharynx (C6)to the stomach.
- Traverse diaphragm at level of T10.
- **Muscular wall arrange in 2 layers:**
  1. Outer longitudinal.
  2. Inner circular.
- **Innervation:**
  - Upper 3rd : voluntary.
  - Middle 3rd : mixed.
  - Lower 3rd : involuntary.

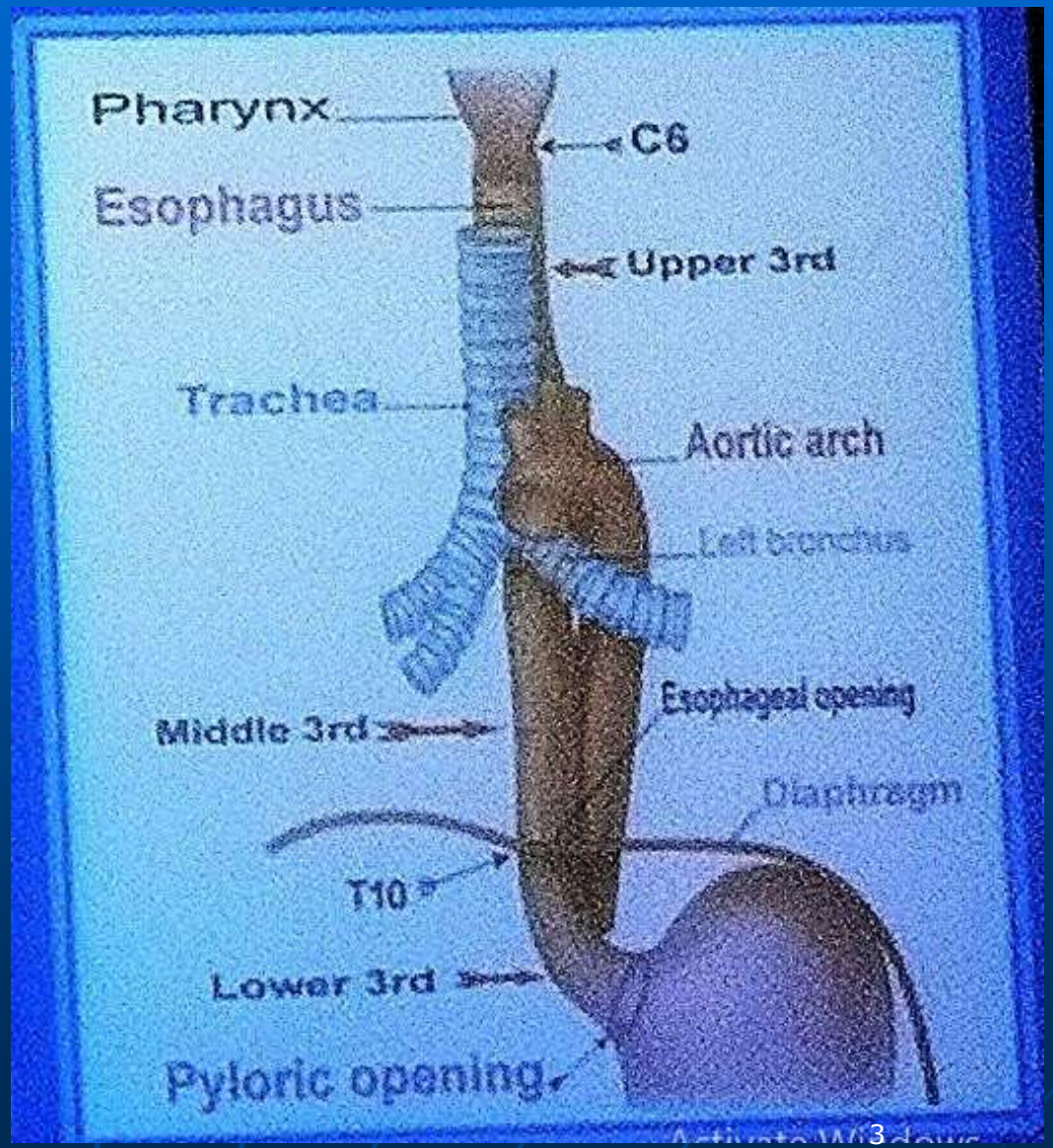

Abdominal Esophagus

- Shortest part.
- About 1.5 cm long.
- AS: Celiac artery.
- Vs: portal vein.

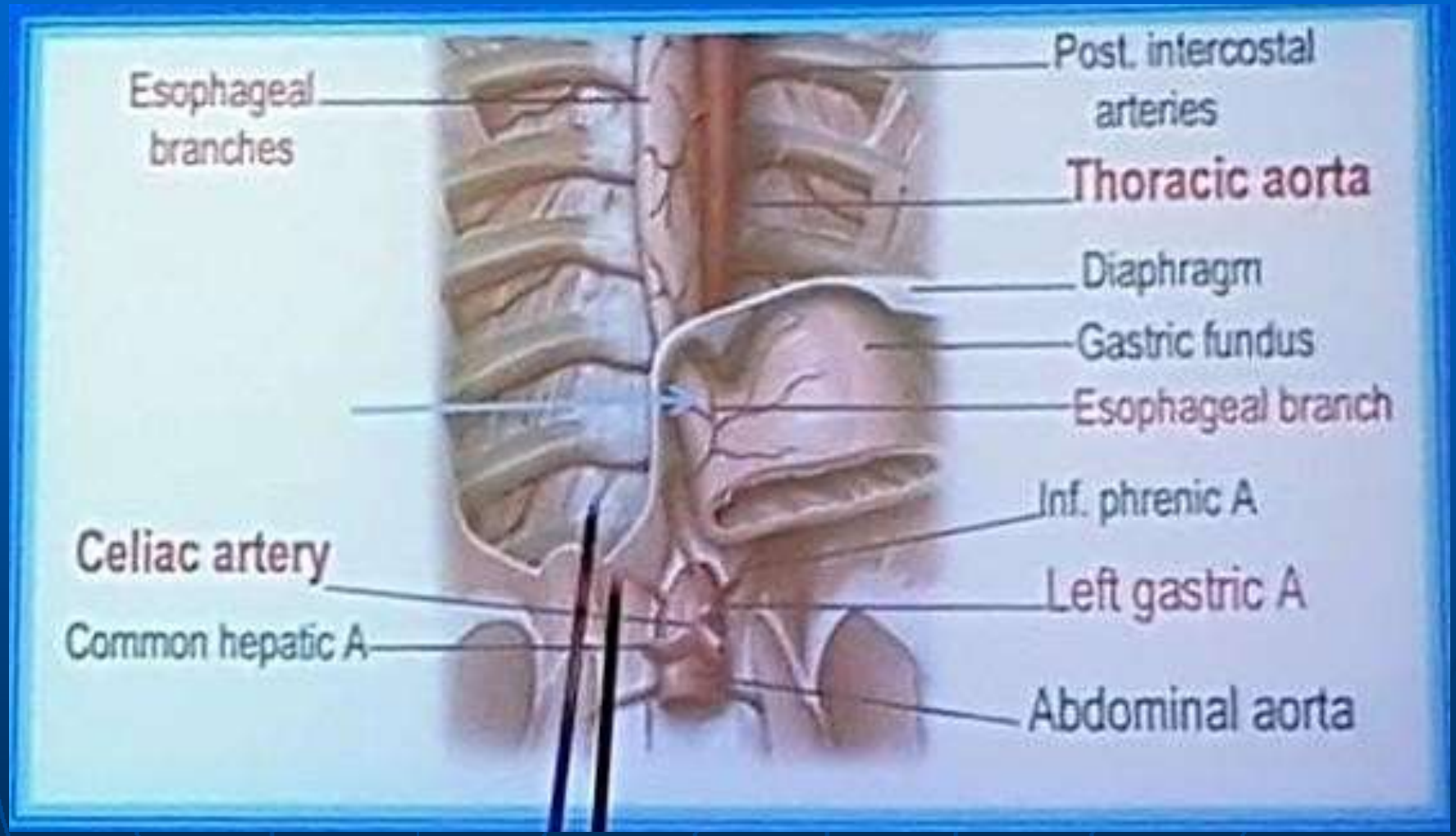

Stomach

- Upper dilated part of G.I.T.
- Shape and size depends on:
  - Position of a person.
  - Habits of eating.

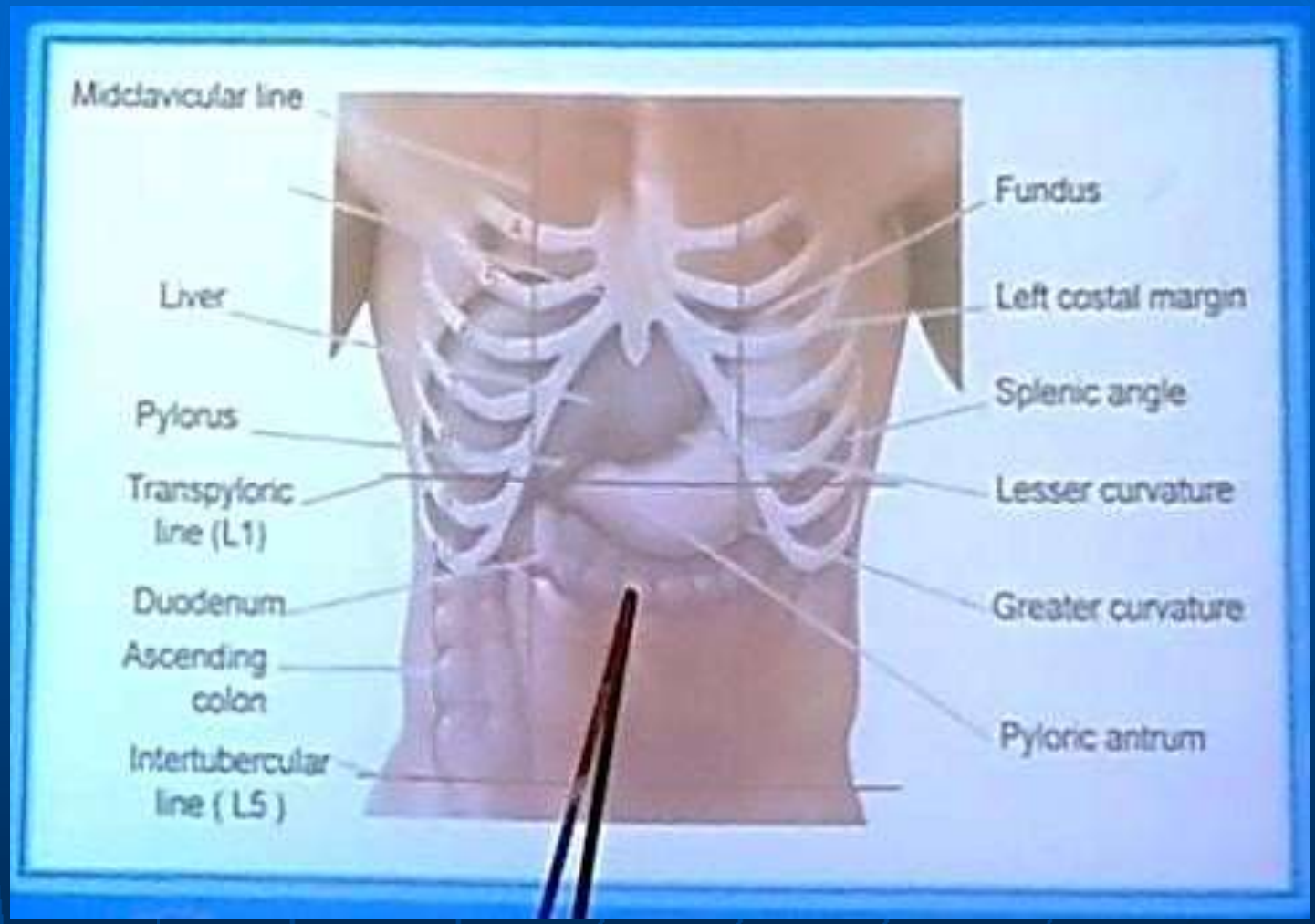

Stomach- Parts

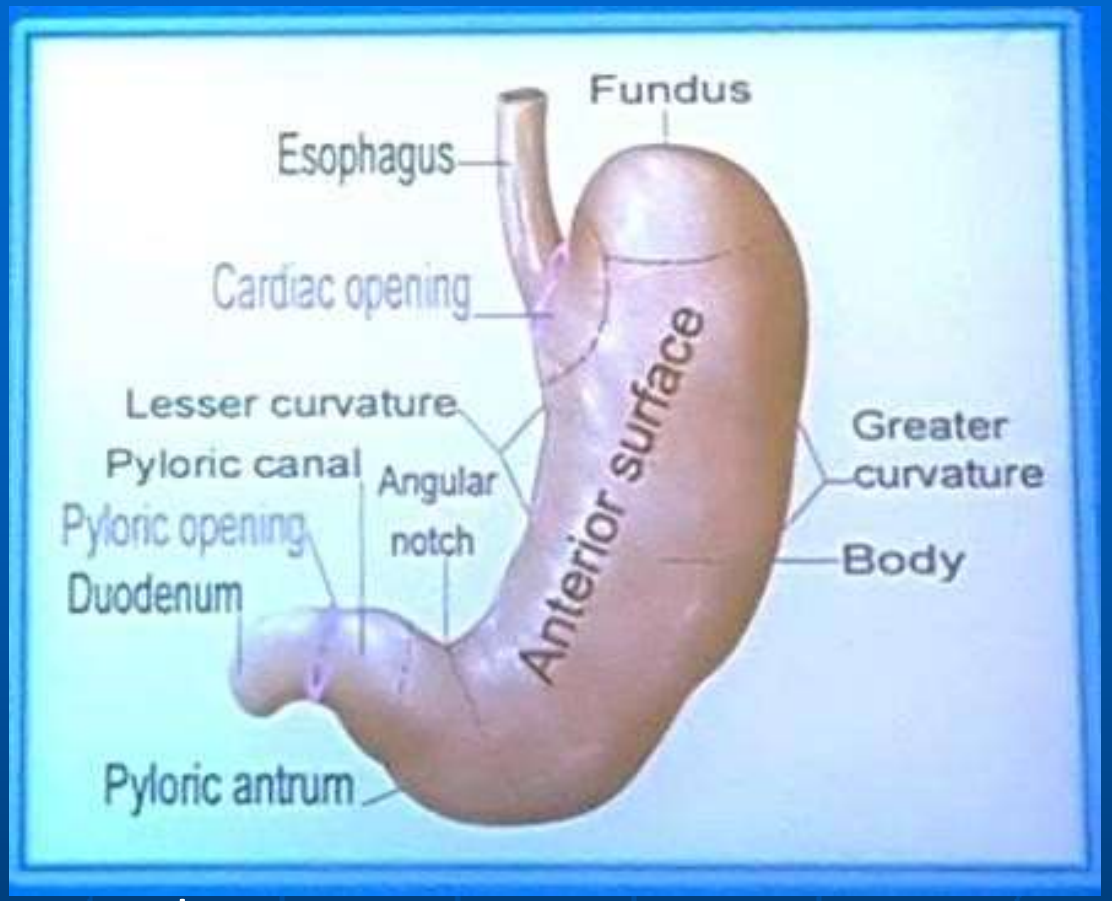

- **<u>2 Openings :</u>** Cardiac, Pyloric. Relatively fixed at these ends.
- **<u>2 Surfaces :</u>**Anterior, posterior
- **<u>2 Curvatures :</u>**
  - Greater ➡ left.
  - Lesser ➡ Right.
    - ✓ **<u>Angular notch:</u>**
      At lesser curvature that marks body from pylorus.

- Parts: Fundus, Body, Pylorus

Stomach

<u>Wall form of 4 layers:</u>

1. Mucosa.
2. Submucosa.
3. Musculosa.
4. Serosa.

Mucosa: has longtuidinal folds in empty stomach

<u>Gastric canal:</u>

-Between 2 permanent mucosal folds opposite lesser curvature.

- Common site of gastric ulcer.

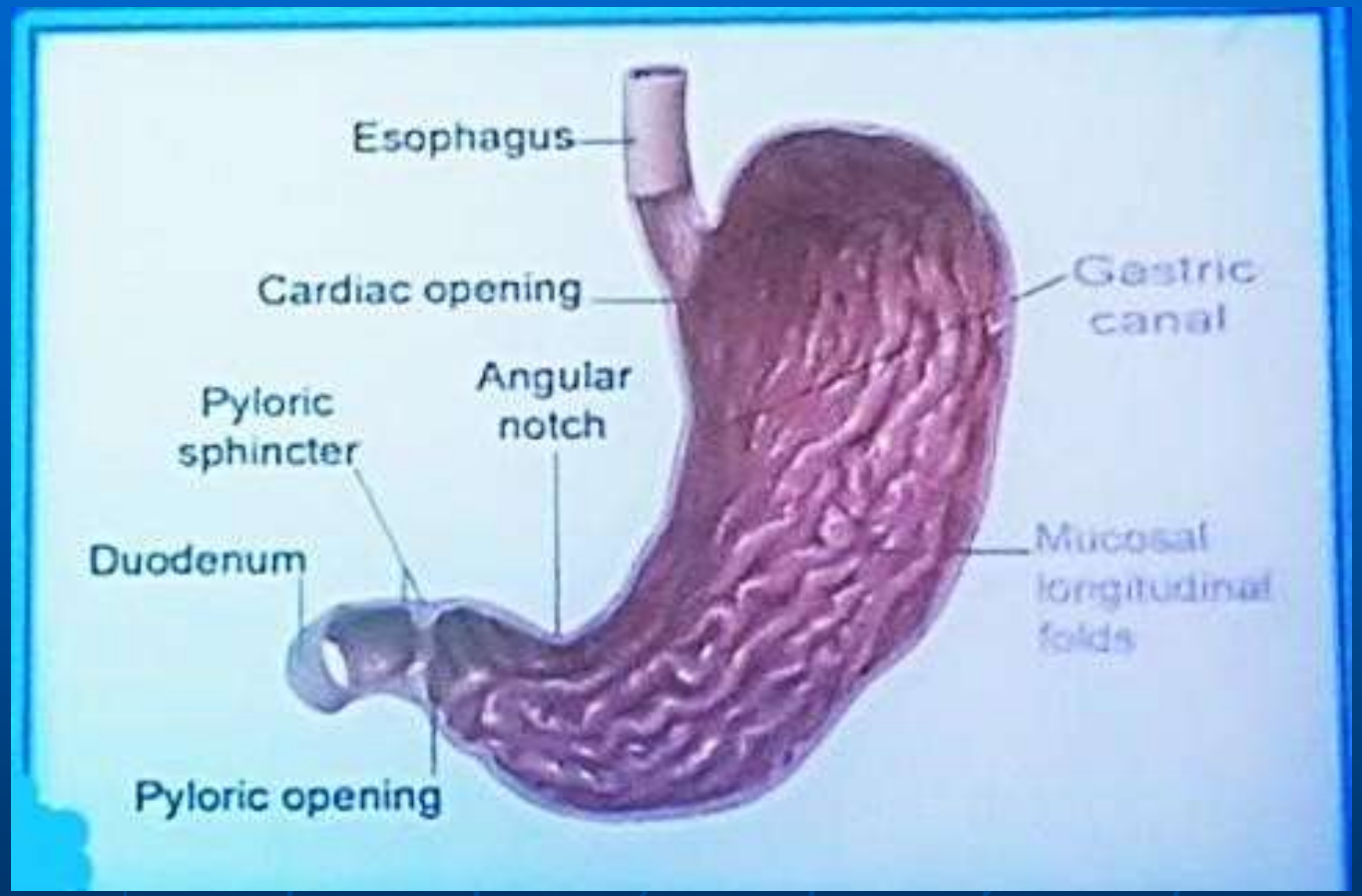

Stomach- Muscular wall

Musculosa form of 2 layers:

1. Outer longitudinal.
2. Middle circular.

- Pyloric sphincter: Marked thickening of circular layer that control emptying of stomach.

3. Inner oblique.

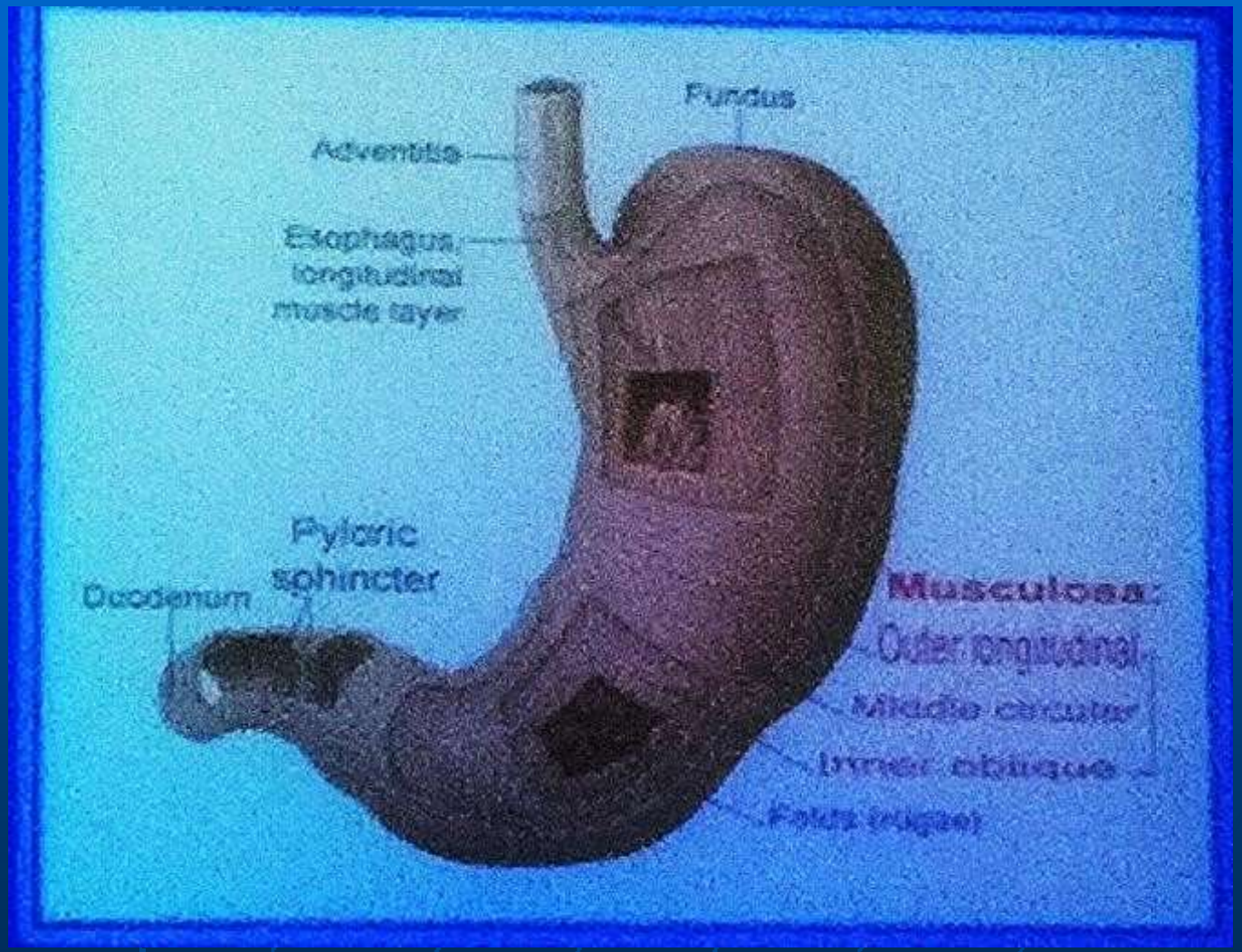

Artery: branches from Celiac A.

Veins: to portal vein.

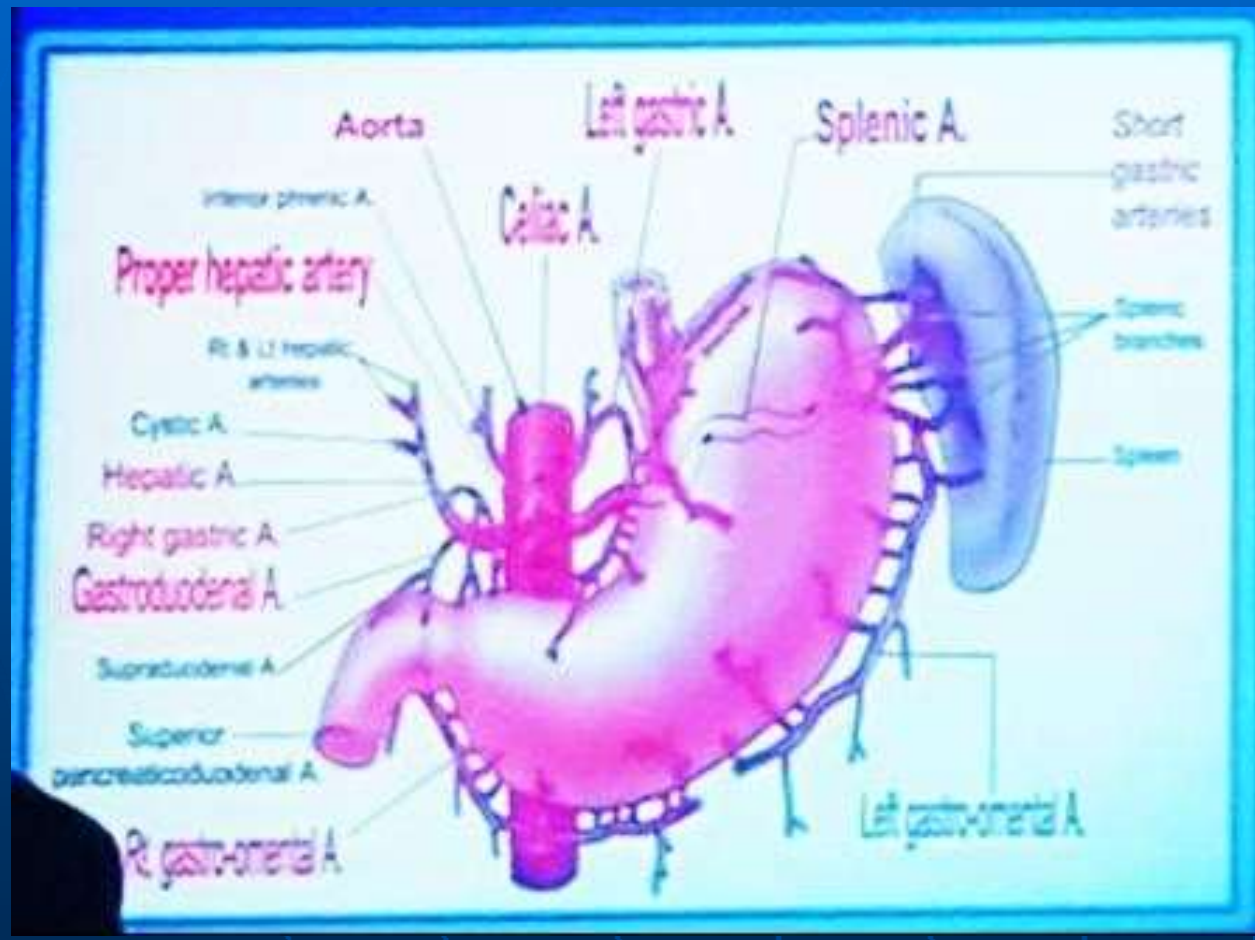

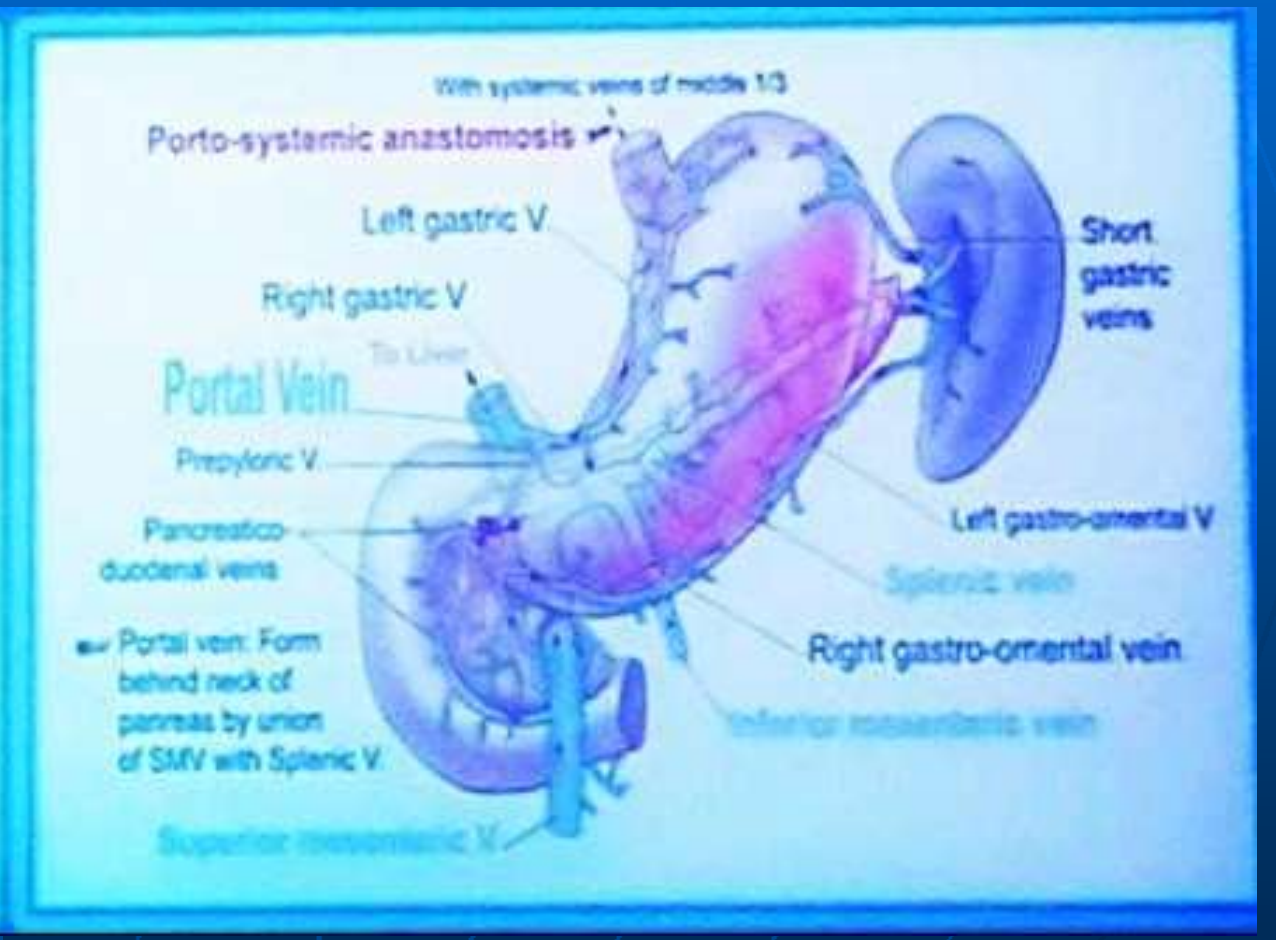

Duodenum

- Capital **G**- shaped tube about 25cm long, extending from pylorus to jejunum.
- Surrounds head of pancreas.
- <u>Retroperitoneal except its proximal and distal inches.</u>
- <u>Divides into 4 parts:</u>

1. First part.
2. Second part.
3. Third part.
4. Fourth part.

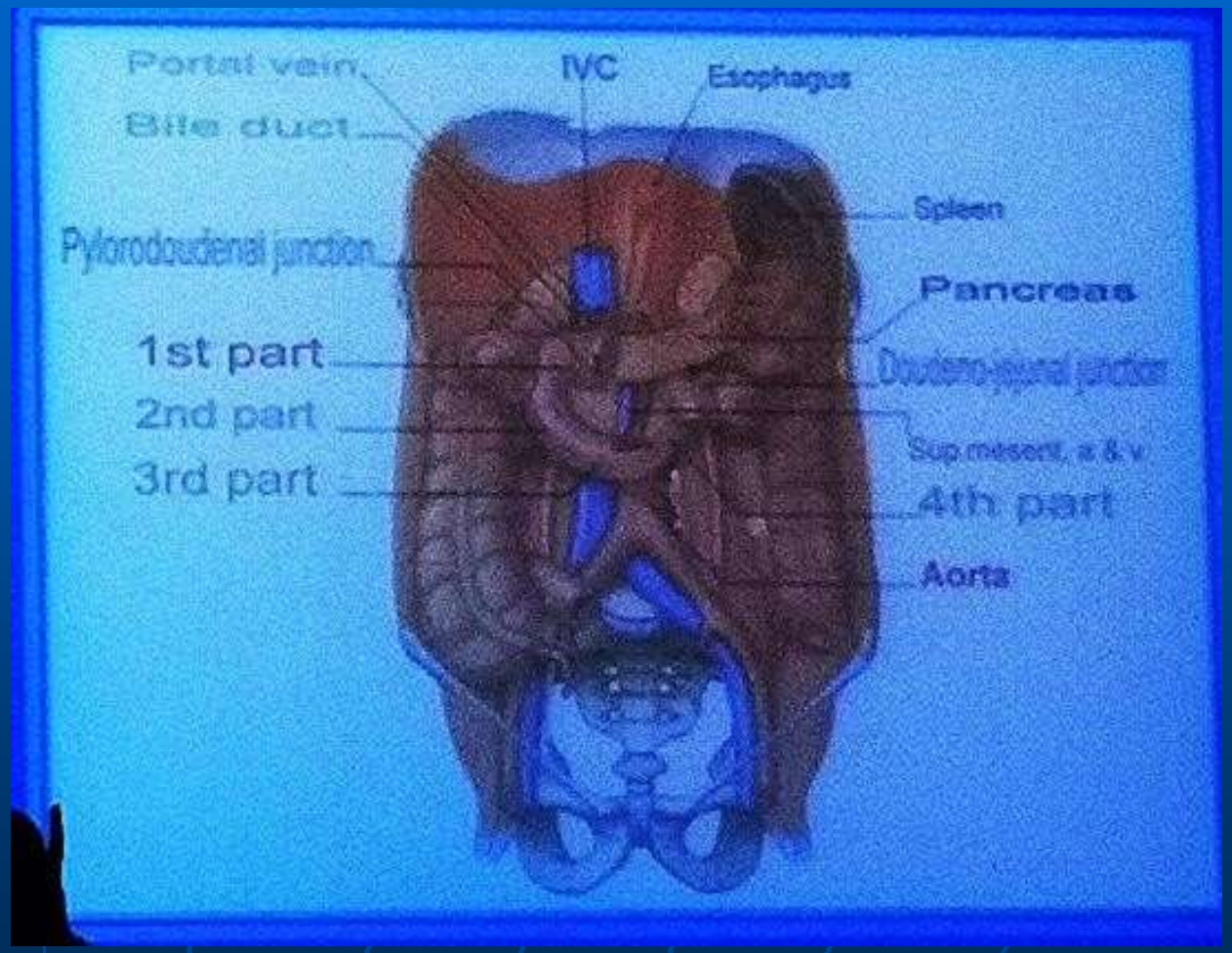

Structures medial to the 2nd part

- Medial structures are:

1. Head of pancreas.
2. Entrance of common bile duct.
3. Entrance of pancreatic ducts.

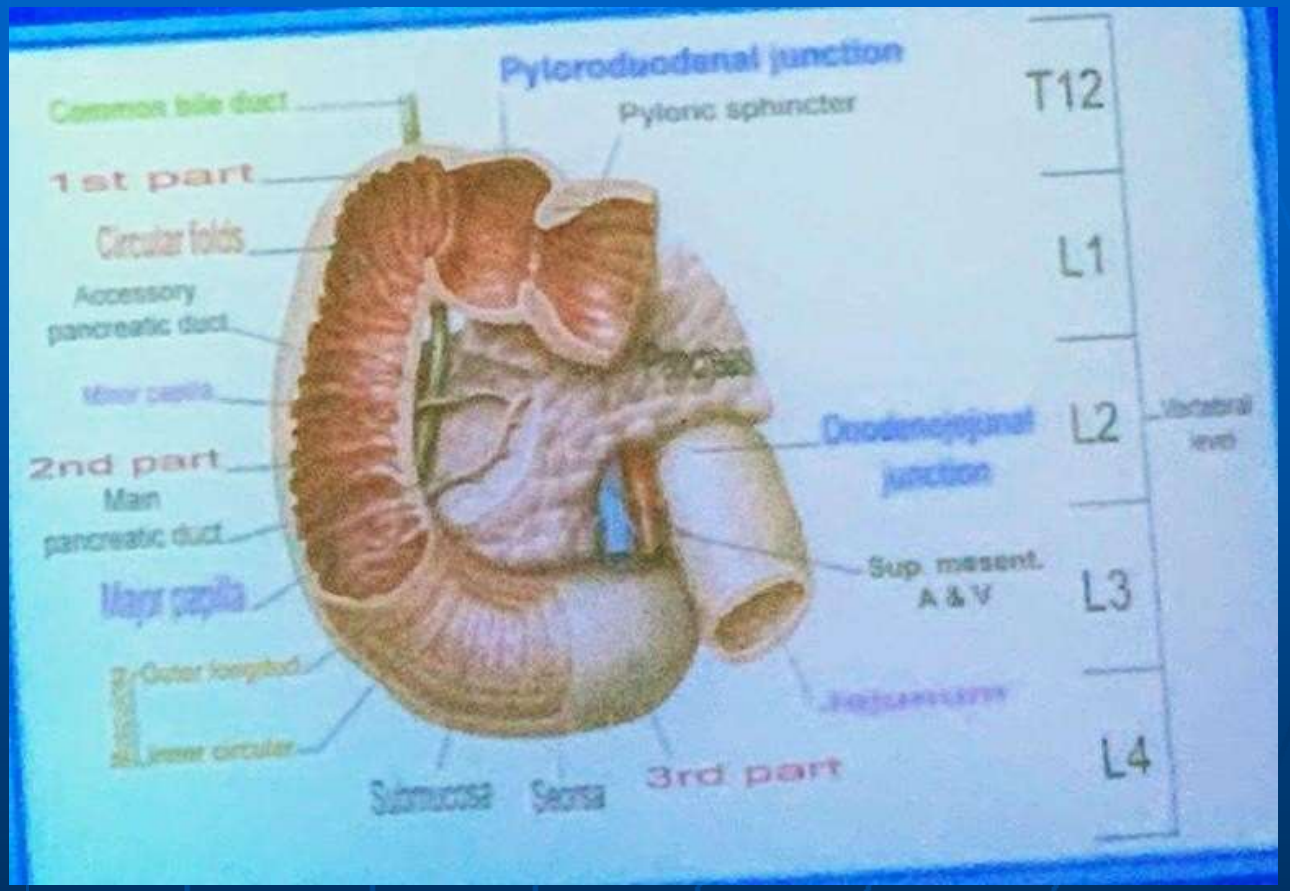

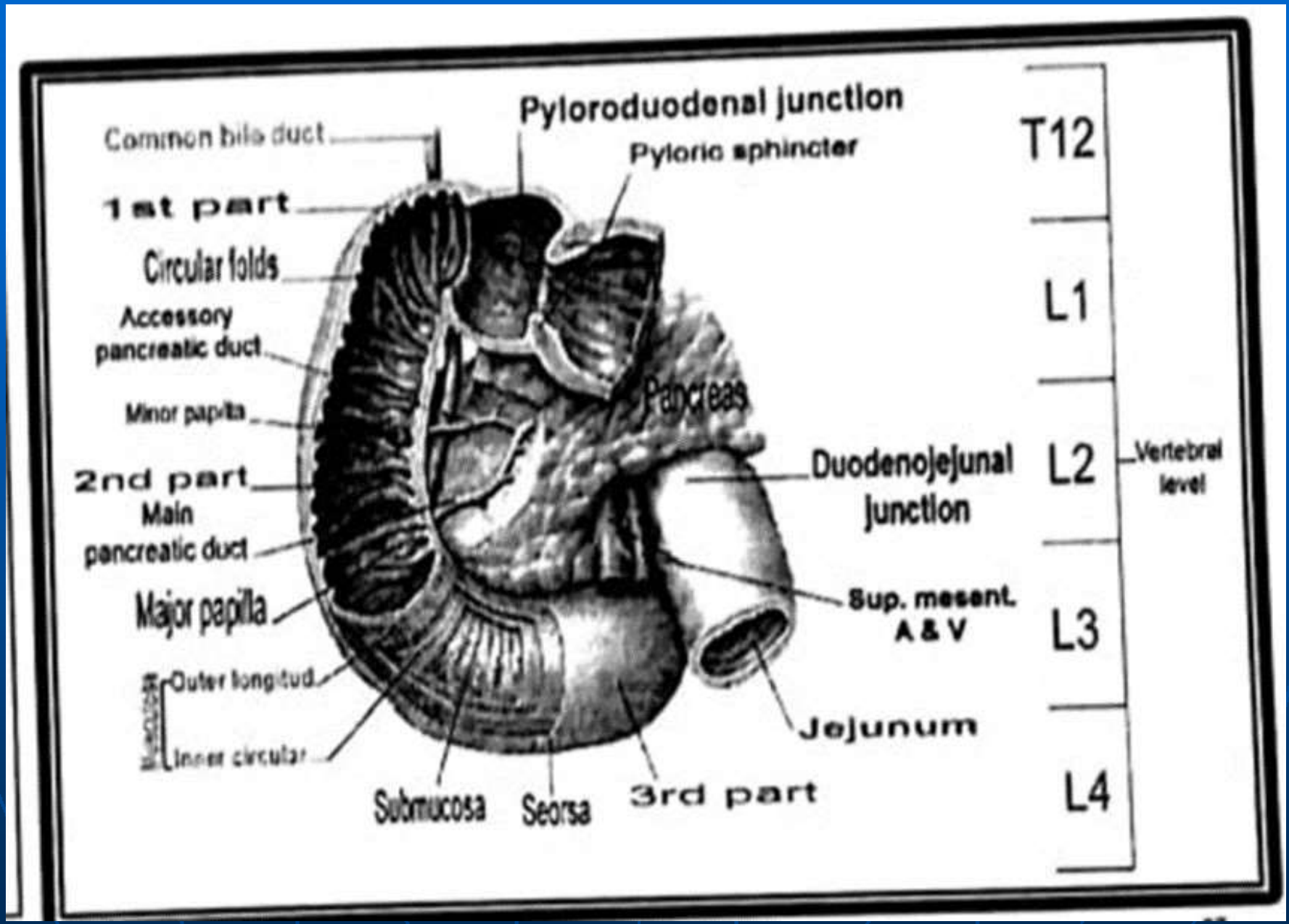
Pyloroduodenal junction
Common bile duct
Pyloric sphincter
1st part
Circular folds
Accessory pancreatic duct
Minor papilla
Pancreas
2nd part
Main pancreatic duct
Major papilla
Duodenojejunal junction
Sup. mesent. A & V
Outer longitud.
Inner circular
Jejunum
Submucosa
Seorsa
3rd part
T12
L1
L2
L3
L4
Vertebral level

Duodenum- Arteries, veins

- The site of entrance of the common bile duct, marks the location of union between the foregut and midgut.
- According to development, it divides into 2 halves:
  - Proximal ½ ➡ foregut.
  - Distal ½ ➡ midgut.

- Arteries:
  - Proximal ½ : from celiac artery.
  - Distal ½ : from SMA.
- Veins: by 2 veins ➡ portal veins.

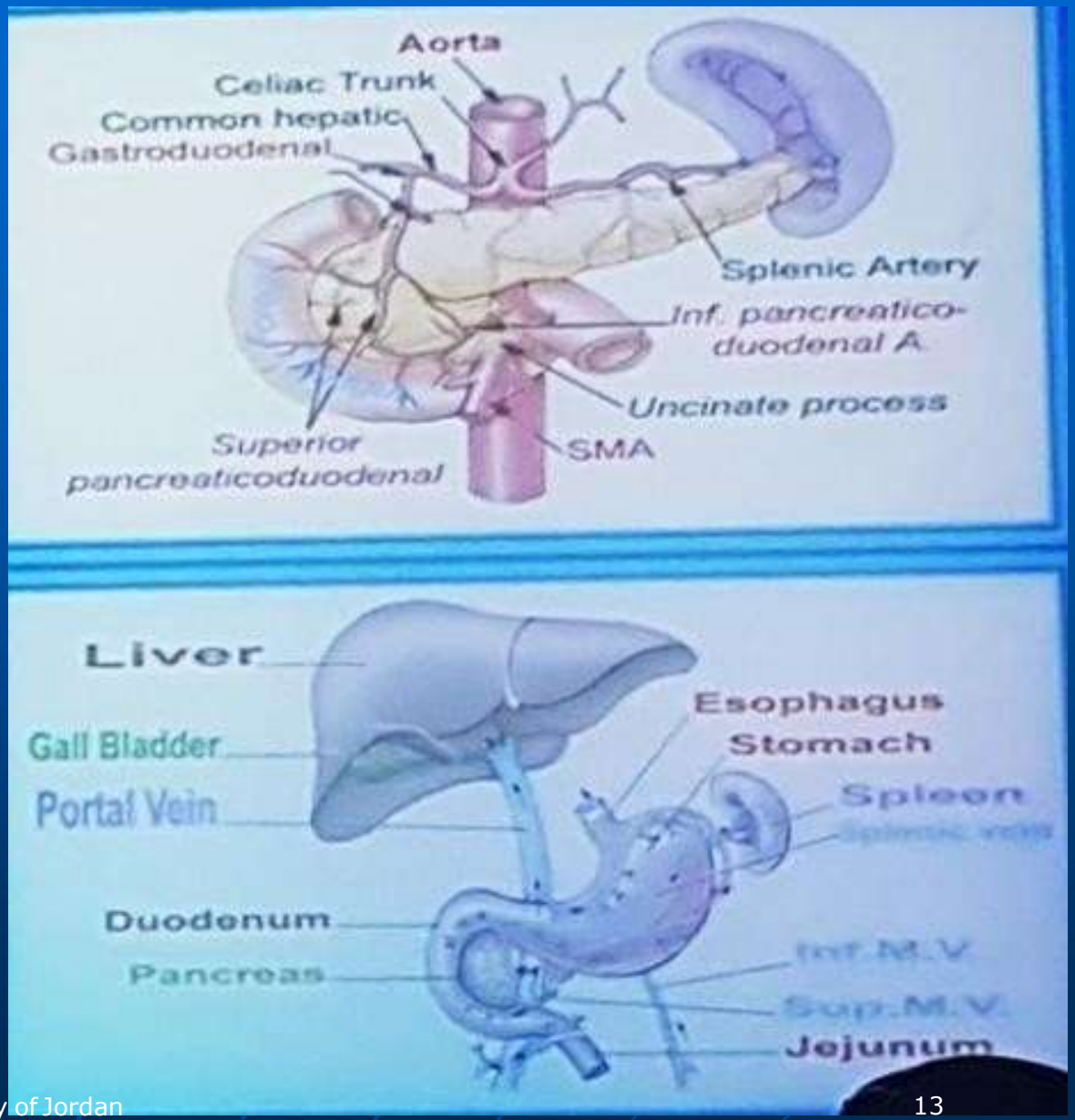

Small intestine

- Mobile intraperitoneal tube.
- About **6m** long.
- Extending from <u>duodenum</u> at Lt. side to <u>cecum</u> at Rt. Side.
- Located around umbilicus.
- Anchored to post. Abdominal wall by fan shaped mesentery.
- <u>Form of two parts:</u>
  - Proximal ⇨ jejunum
  - Distal ⇨ ileum.
- Supply by SM artery.

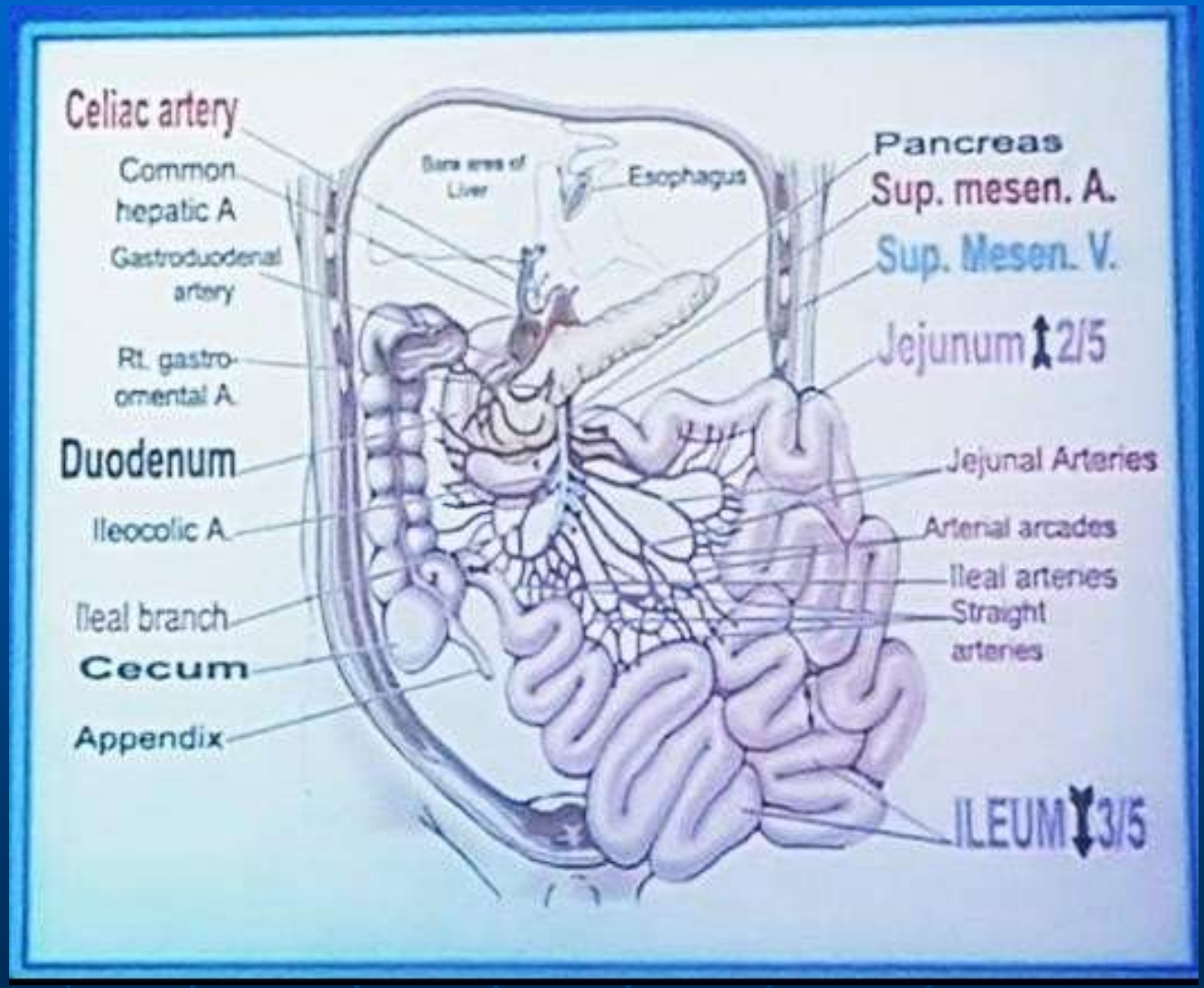

Jejunum

Each part is known by its specific features

ileum

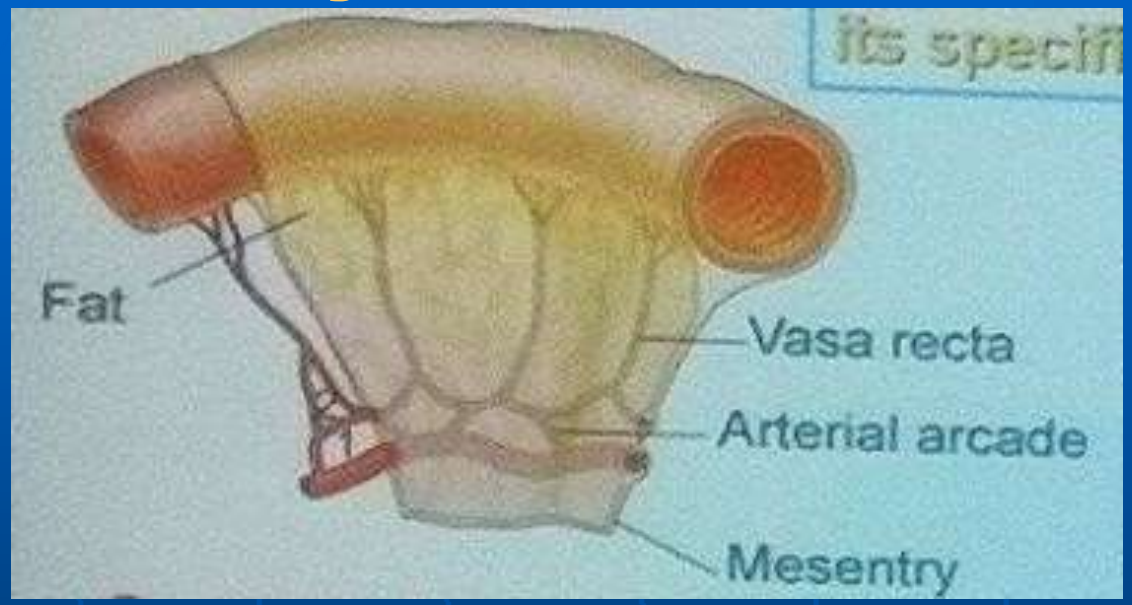

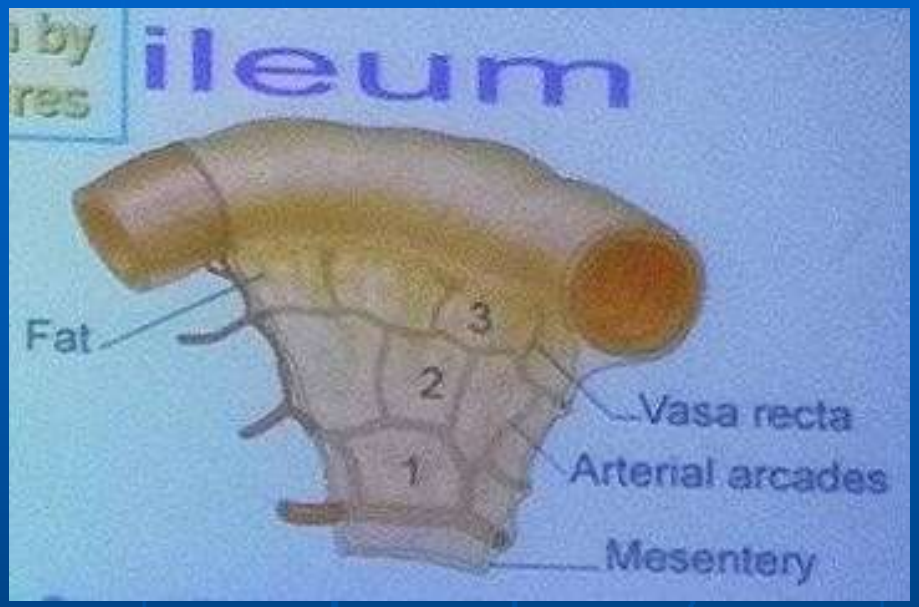

Specifec features :

1. Red in color
2. Proximal 2/5.
3. Wider in diameter.
4. Thick wall
5. Few fat within its mesentery.
6. Simple arterial arcades 1 or 2
7. Located above umbilical level.

Specifec features :

1. Pale in color
2. Distal 3/5.
3. Smaller in diameter.
4. Thin wall
5. Plenty of fat within its mesentery.
6. Complex arterial arcades 1-4
7. Located below umbilical level.