Esophagus



CS in abdominal Esophagus

- About 25 cm long.
- Extends from lower end of pharynx (C6) to the stomach.
- Traverse diaphragm at level of T10.
- **Muscular wall arrange in 2 layers:**
  1. **Outer longitudinal.**
  2. **Inner circular.**
- **Innervation:**
  - Upper 3rd: Voluntary.
  - Middle 3rd: Mixed.
  - Lower 3rd: Involuntary.

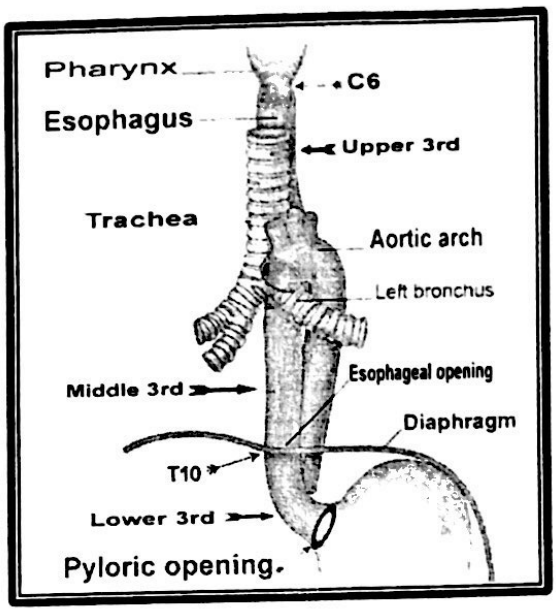

Scanned with CamScanner

Abdominal Esophagus

- Shortest part.
- About 1.5 cm long.
- AS: Celiac artery.
- Vs.: Portal vein.

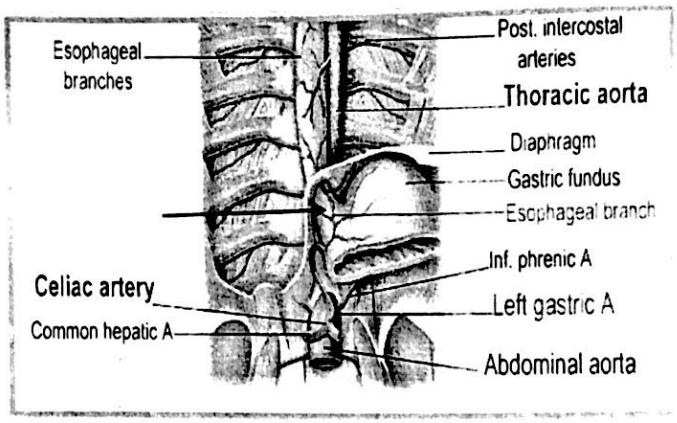

Scanned with CamScanner

Stomach

- Upper dilated part of G.I.T.
- Shape and size depends on:
  - Position of a person.
  - Habits of eating.

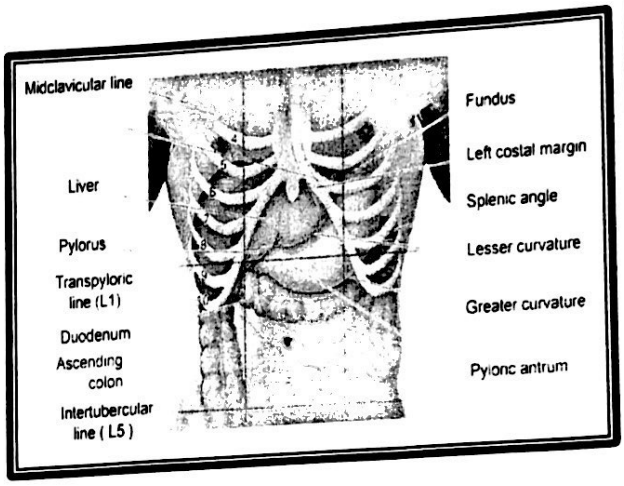

Dr. Maher Hadidi, University of Jordan

Scanned with CamScanner

Stomach- Parts

- **2 Openings:** Cardiac, Pyloric.
  Relatively fixed at these ends.
- **2 Surfaces:** Anterior, Posterior
- **2 Curvatures:**
  - Greater ➡ Left
  - Lesser ➡ Right
    - ✓ **Angular notch:**
      At lesser curvature that marks body from pylorus.
- Parts: Fundus, Body, Pylorus.

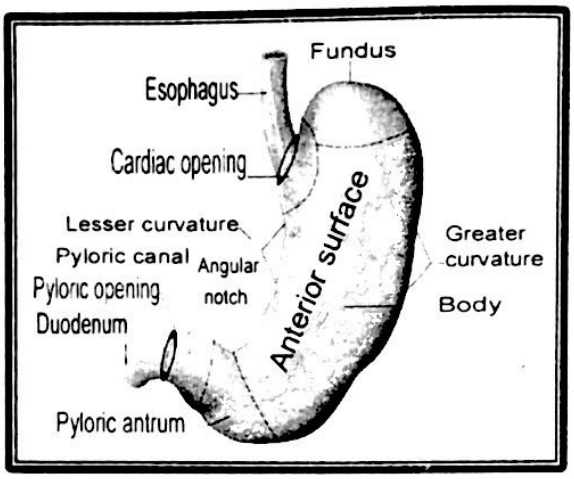

Scanned with CamScanner

Stomach

Wall form of 4 layers:

1. Mucosa
2. Submucosa
3. Musculosa
4. Serosa

Mucosa: Has longitudinal folds in empty stomach.

Gastric canal:

- Between 2 permanent mucosal folds opposite lesser curvature.
- Common site of gastric ulcer.

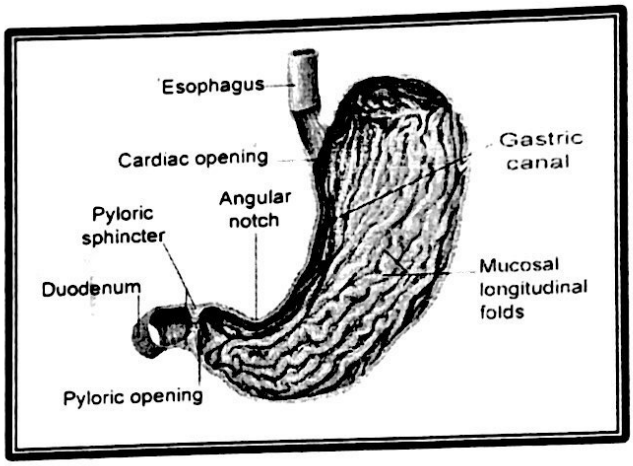

Scanned with CamScanner

Stomach-
Muscular wall

Musculosa form of 3 layers:

1. Outer longitudinal.
2. Middle circular.
   - Pyloric sphincter: Marked thickening of circular layer that control emptying of stomach.
3. Inner oblique.

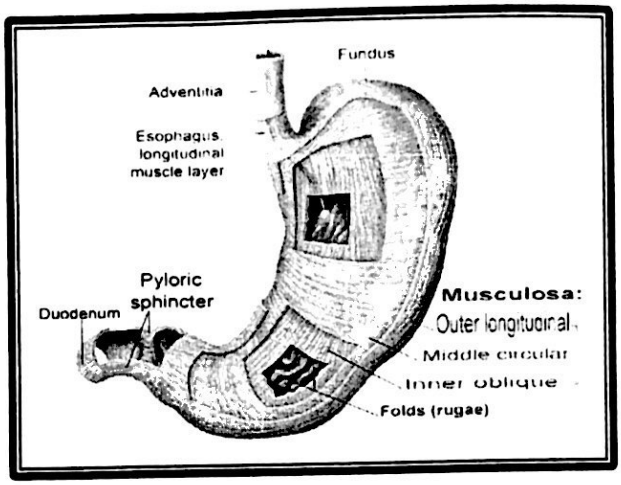

Scanned with CamScanner

Artery: branches from Celiac A.

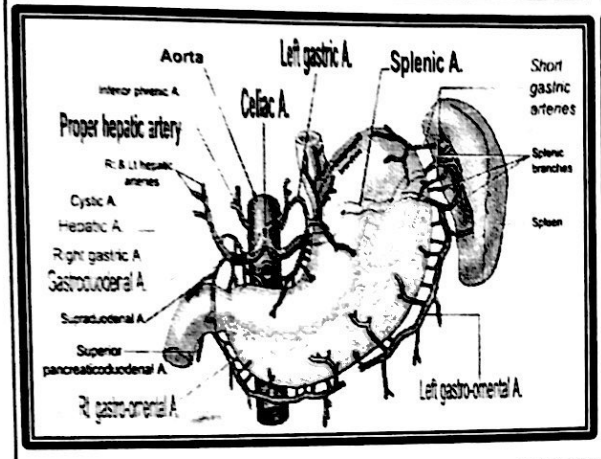

Veins: To portal vein.

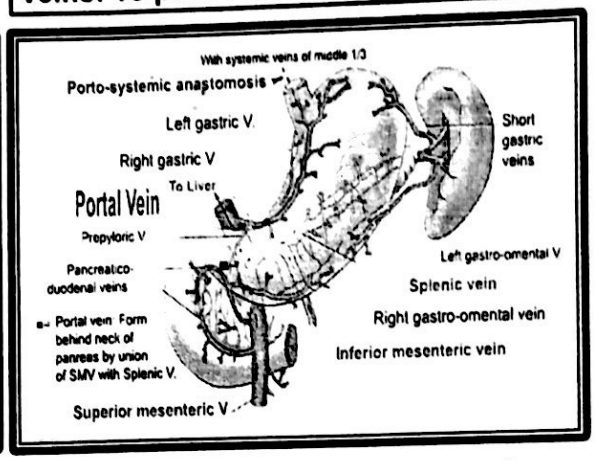

Spring 2019 Dr. Maher Hadidi, University of Jordan 16

Scanned with CamScanner

Duodenum

- Capital **G**-shaped tube about 25cm long, extending from pylorus to jejunum.
- Surrounds head of pancreas.
- <u>Retroperitoneal except its proximal and distal inches.</u>
- <u>Divides into 4 parts:</u>

1. First part.
2. Second part.
3. Third part.
4. Fourth part.

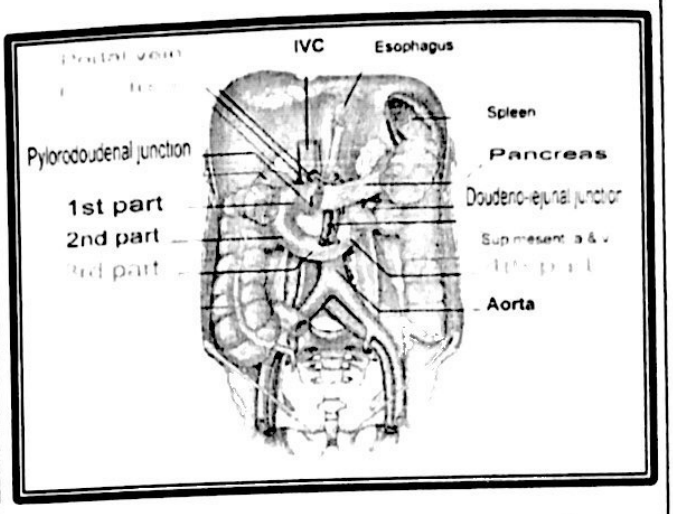

Scanned with CamScanner

Structures medial to the 2nd part

- Medial structures are:
  1. Head of pancreas.
  2. Entrance of common bile duct.
  3. Entrance of pancreatic ducts.

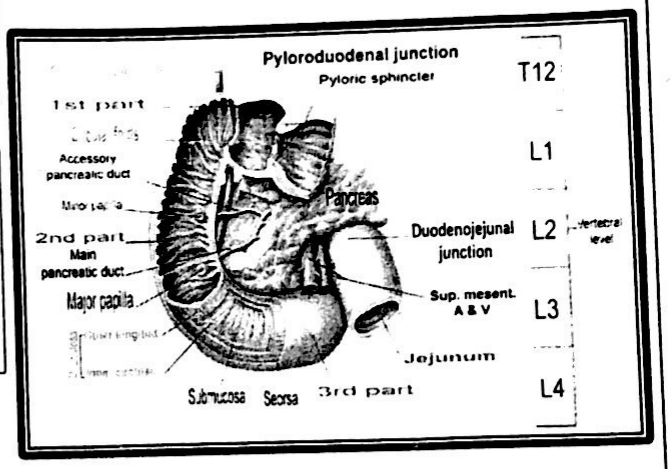

Scanned with CamScanner

Duodenum- Arteries, Veins

- The site of entrance of the common bile duct, marks the location of union between the foregut and midgut.
- According to development, it divides into 2 halves:
  - Proximal ½ ➡ Foregut.
  - Distal ½ ➡ Midgut.
- Arteries:
  - Proximal ½: From celiac A.
  - Distal ½: From SMA.
- Veins: by 2 veins ➡ Portal veins.

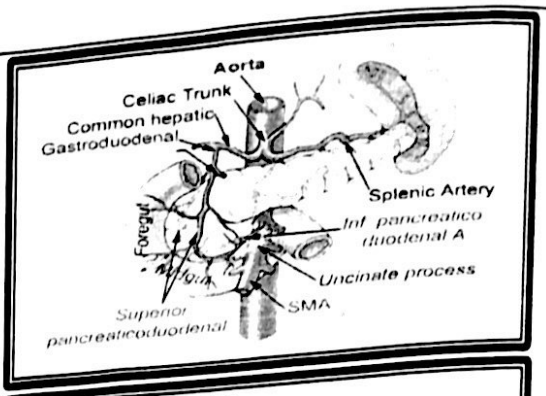

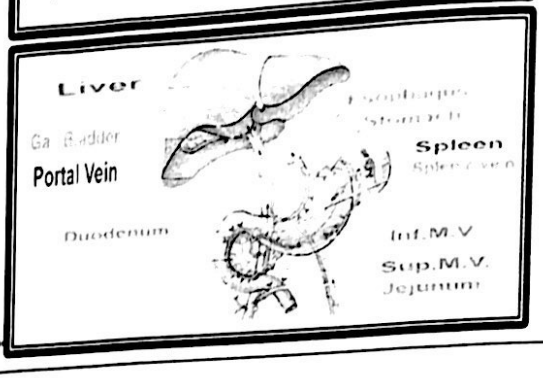

Spring 2019

Scanned with CamScanner

Small intestine

- Mobile intraperitoneal tube.
- About **6m** long.
- Extending from duodenum at Lt. side to cecum at Rt. side.
- Located around umbilicus.
- Anchored to post. abdominal wall by fan-shaped mesentery.
- Form of two parts:
  - Proximal ➡ Jejunum.
  - Distal ➡ ileum.
- Supply by SM Artery.

First part of colon (large intestine)

a tissue that attaches the intestines to the abdominal wall

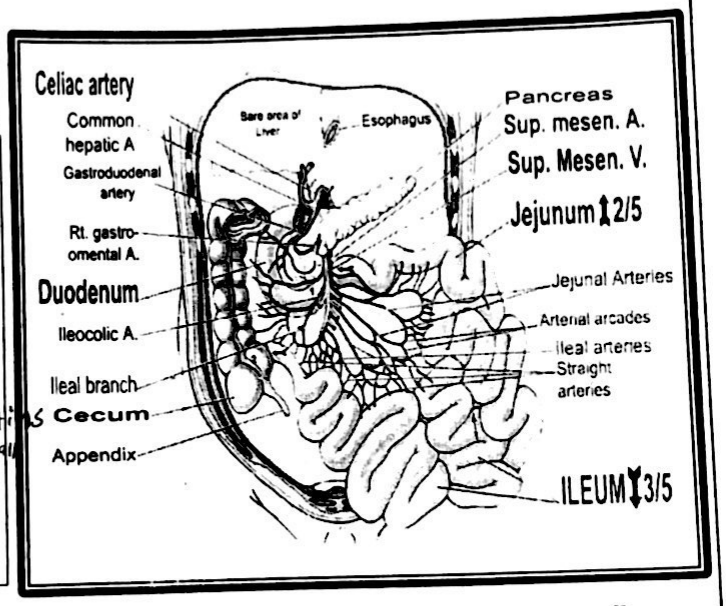

Scanned with CamScanner

Jejunum | Each part known by its specific features | ileum

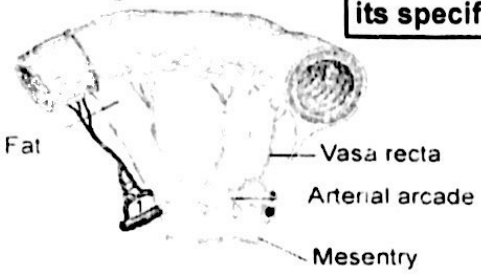

Specific Features:

1- Red in color.
2- Proximal 2/5.
3- Wider in diameter.
4- Thick wall.
5- Few fat within its mesentry.
6- Simple arterial arcades 1 or 2.
7- Located above umbilical level.

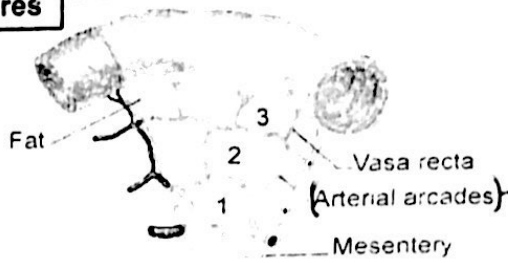

Arterial Arches

Specific Features:

1- Pale in color.
2- Distal 3/5.
3- Smaller in diameter.
4- Thin wall.
5- Plenty of fat within its mesentry.
6- Complex arterial arcades 1 - 4
7- Located below umbilical level.

Scanned with CamScanner