Implantation-1

Many events in the 2nd week occurs in twos.

To memorize these events recall "rule of twos".

Day 6

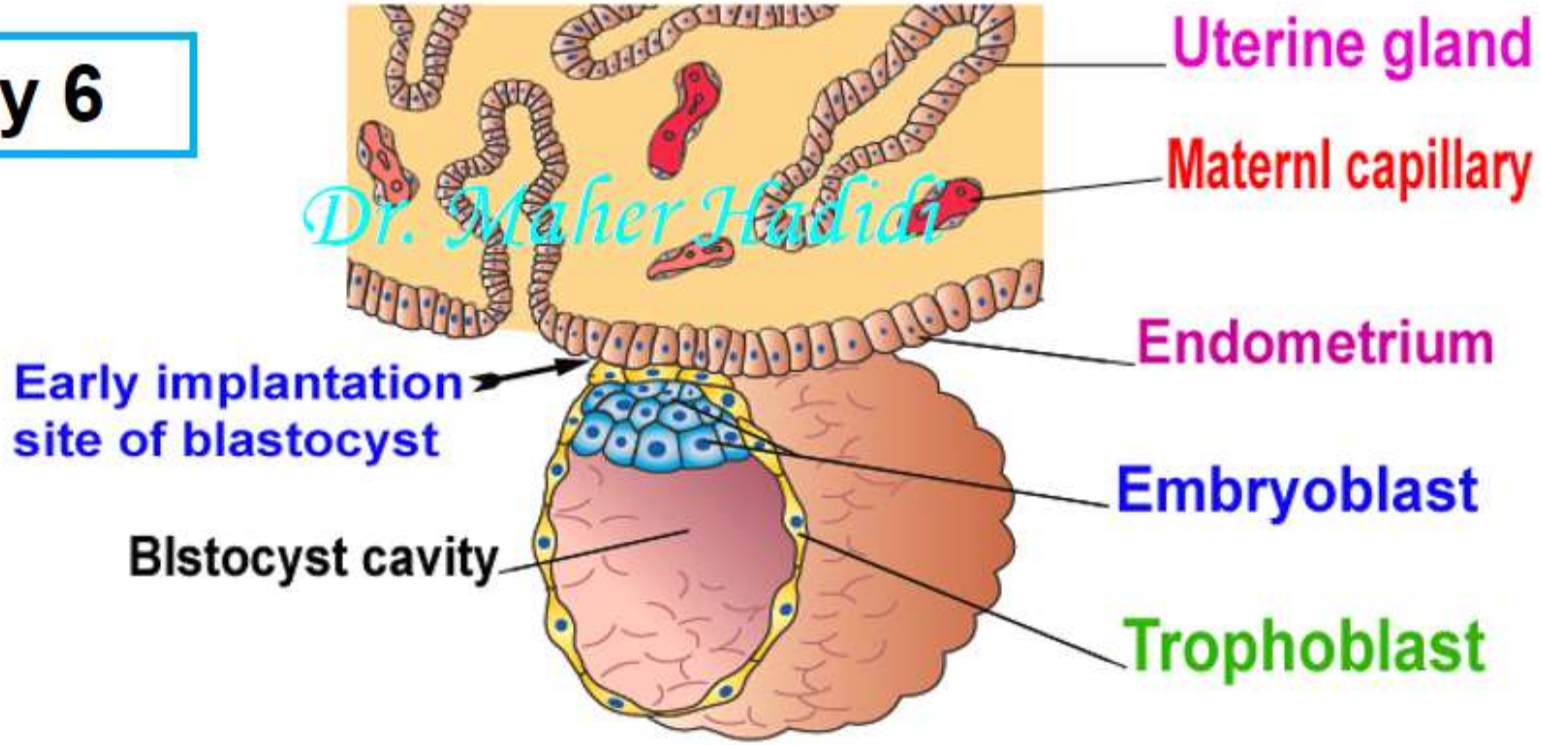

At 6 days after fertilization, the trophoblast attached to the endometrium at the embryonic pole of the blastocyst.

Day 8-A

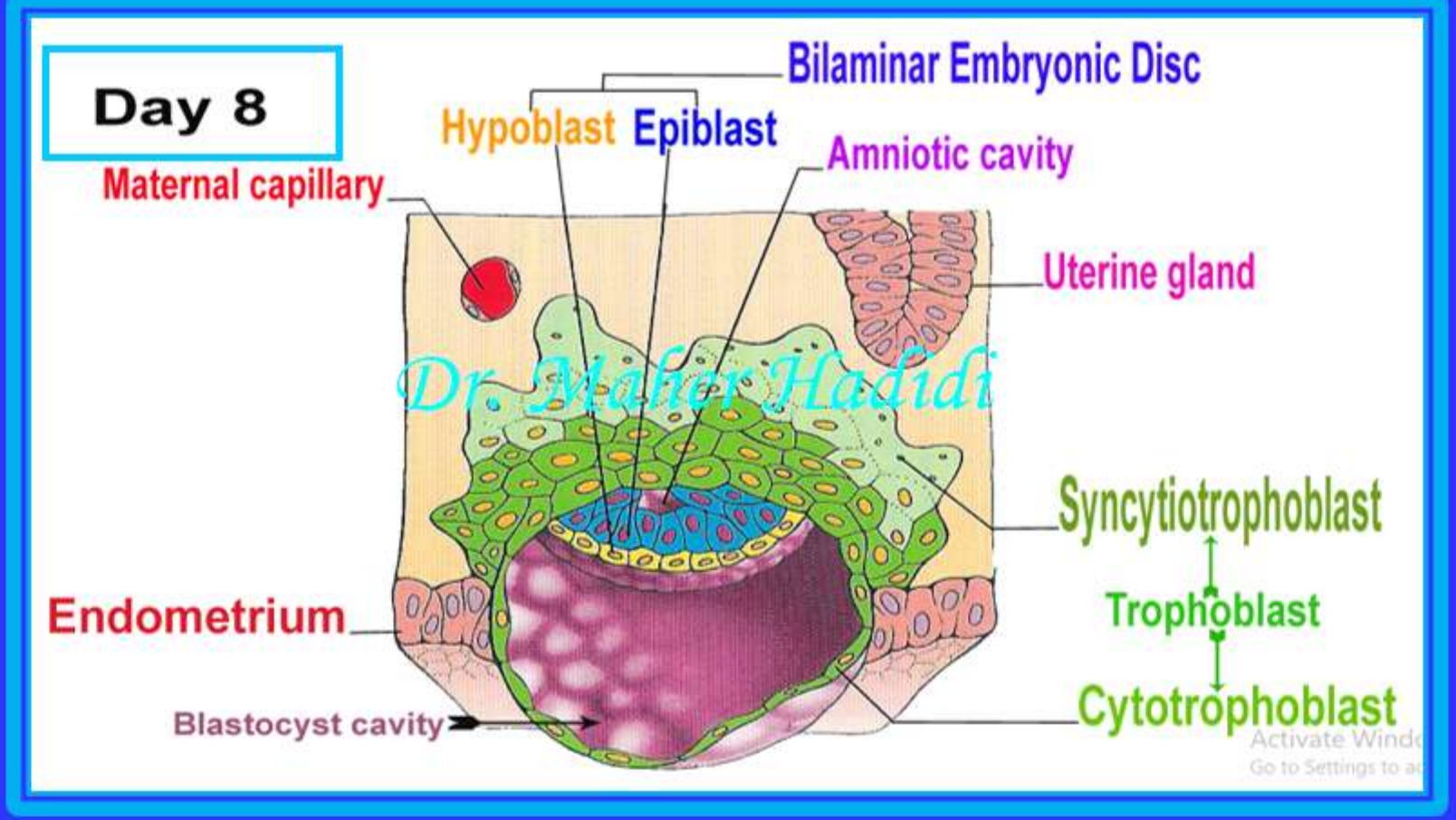

- **At Day 8**, as the trophoblast contacting the endometrium, the trophoblast is **induced** to differentiate into <u>two layers:</u>

1. **Inner cytotrophoblast** (mononucleated single cells).
2. **Outer syncytiotrophoblasts** (a mass of cytoplasm containing many dispersed nuclei, without cell membrane).

➢Both layers form the fetal part of the placenta (**Chorion**).

Day 8- B

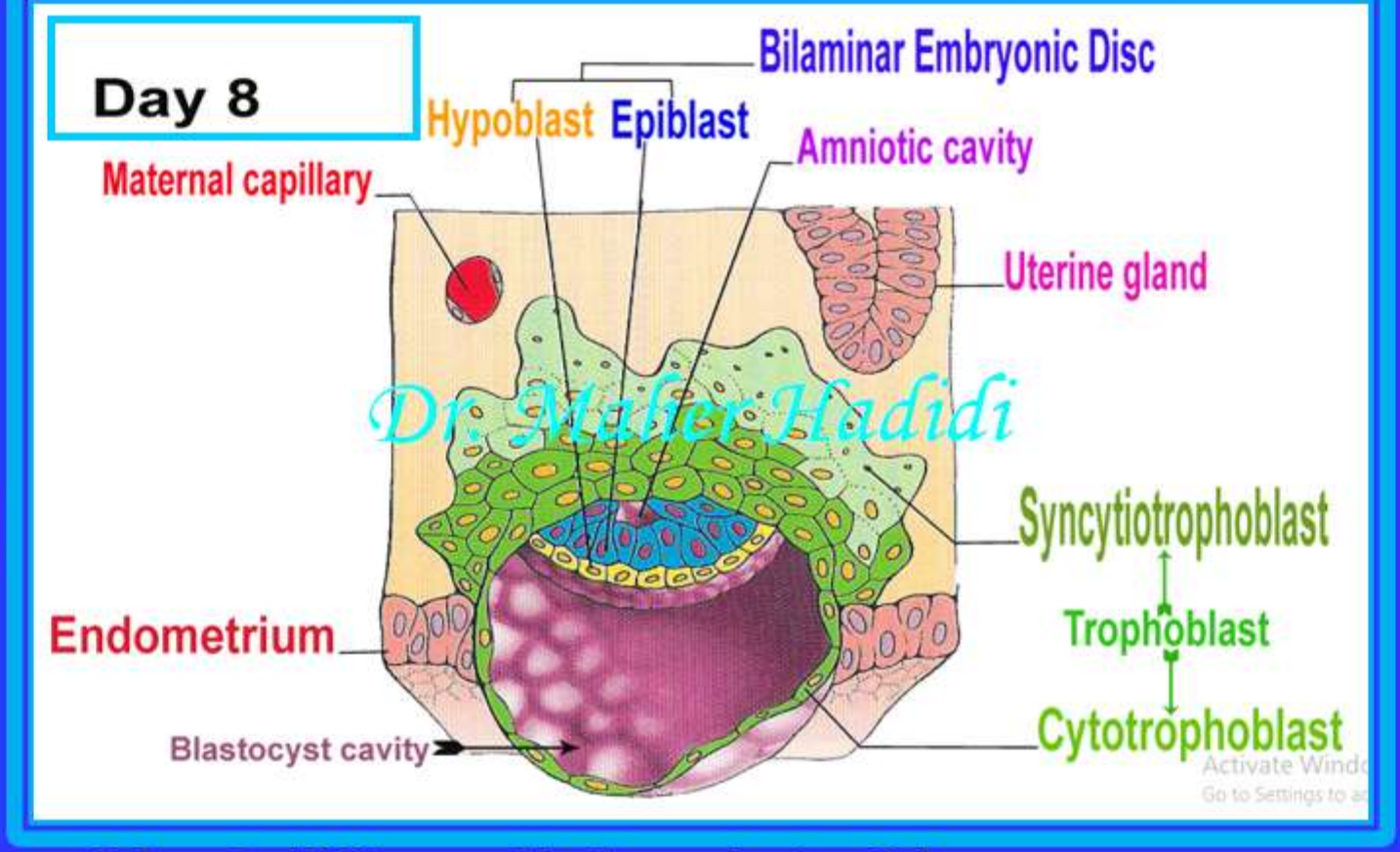

- **Embryoblast differentiates into <u>2 layers:</u>**
  1. **Epiblast.** (Columnar cells).
  2. **Hypoblast.** (Cuboidal cells)
- The resulting 2-layeres is called <u>Bilaminar embryonic disc</u>.
- Thereafter, a small **Amniotic cavity** appears within the epiblast cells.

Day 8- C

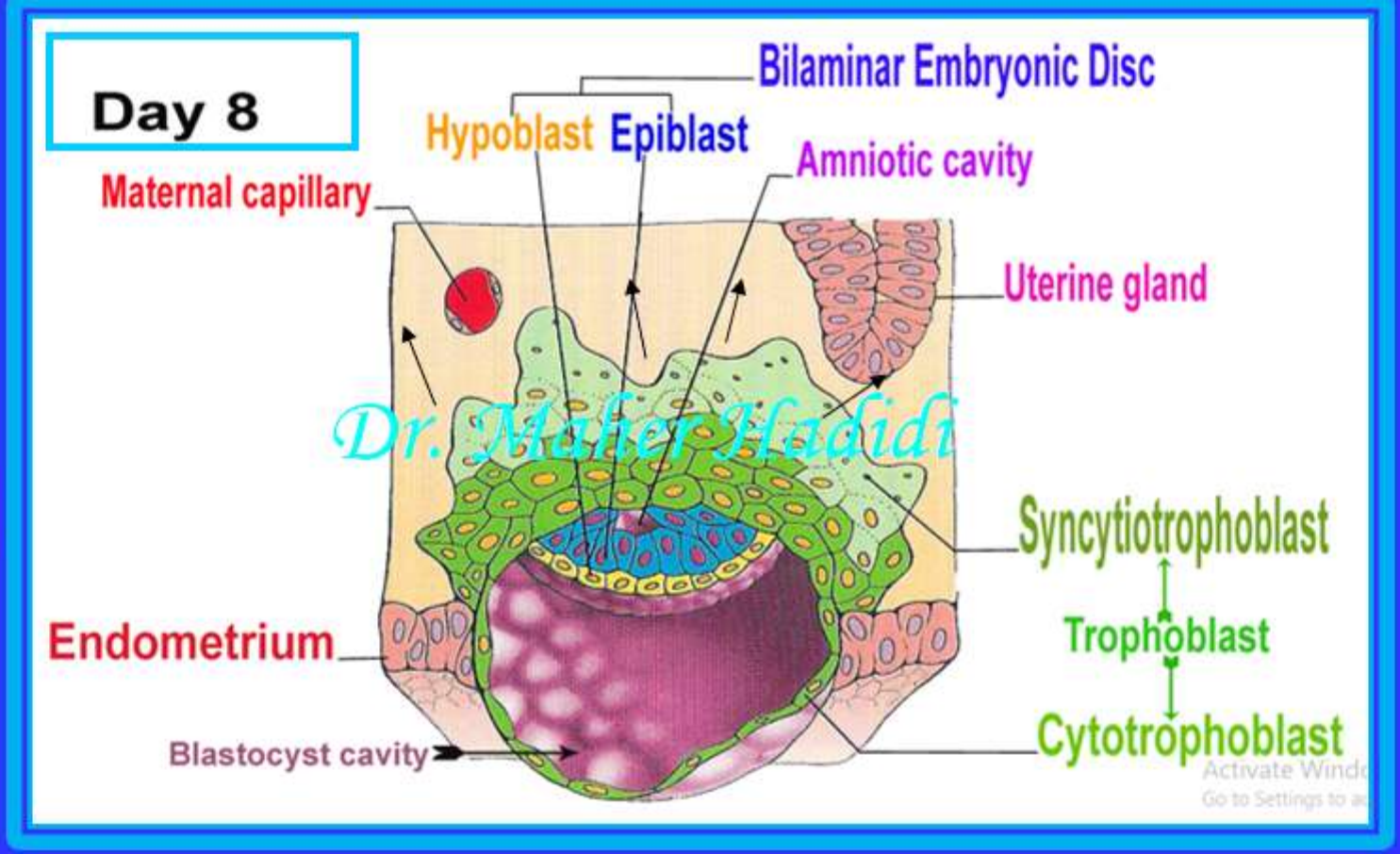

- The syncytiotrophoblasts **invades** the endometrium and bury the blastocyst within the endometrium.
- Syncytiotrophoblast cells secretes **hCG** hormone which, detected in maternal urine (+ve pregnancy test). Interrupts normal sexual cycle.
- This hormone prevents degeneration of the Corpus Luteum and maintains it as **Corpus Luteum of pregnancy.**

Day 9- A

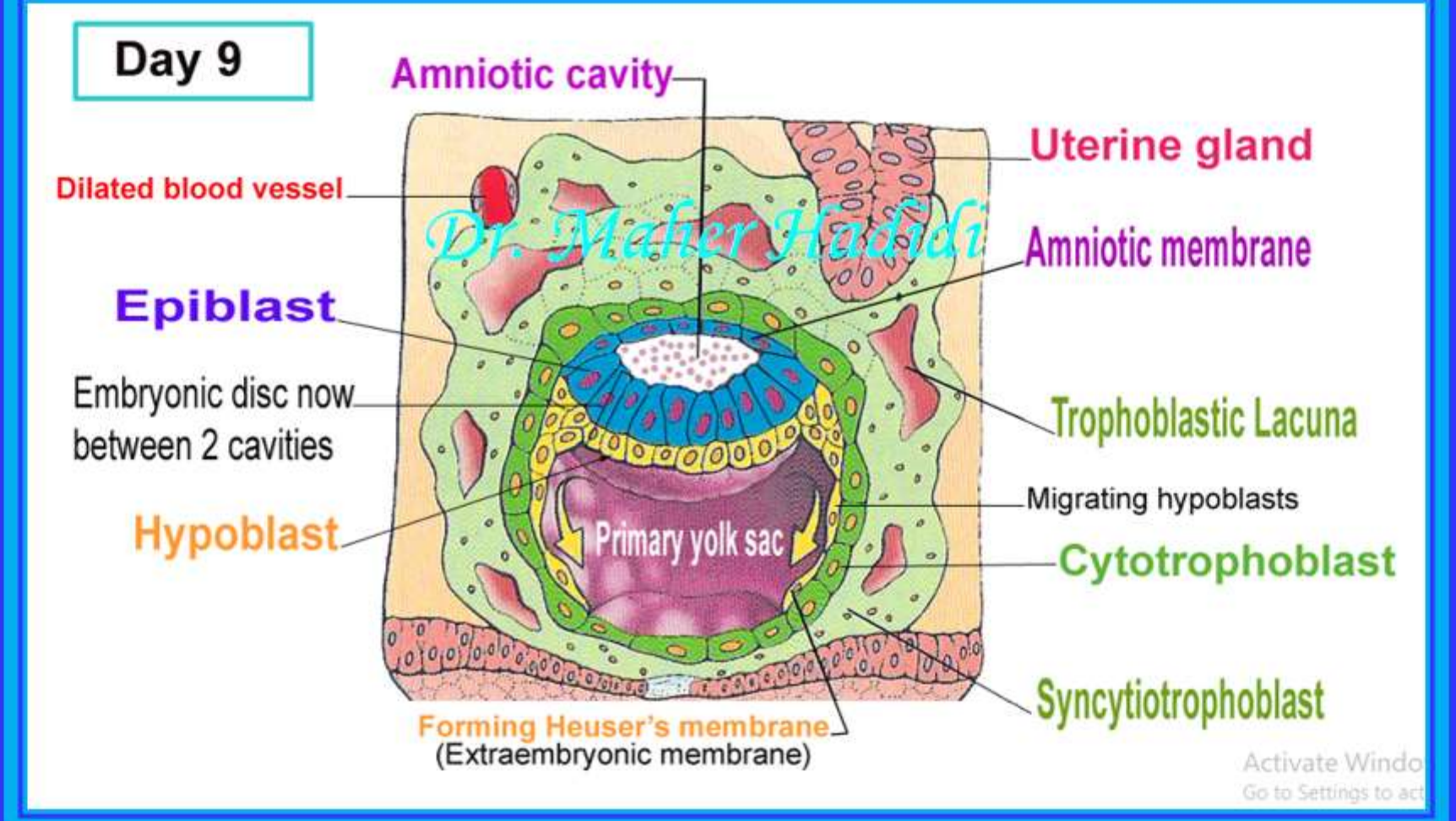

1. Blastocyst completely implanted in the endometrium.
2. Syncytium covers the whole blastocyst and show small fluid-filled cavities that fuse to form the **trophoblastic Lacunae.**

Day 9- B

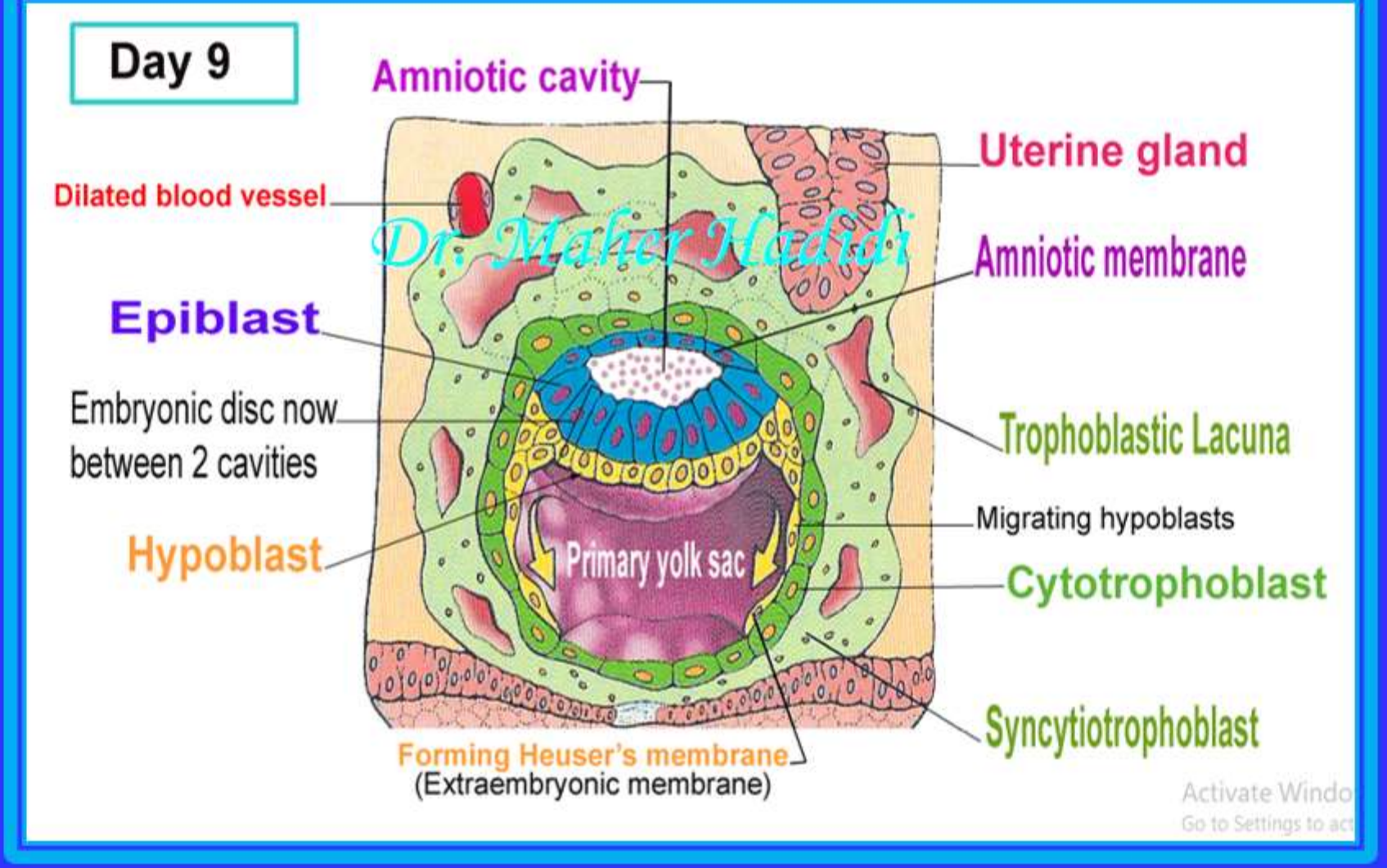

3. Amniotic cavity enlarge and epiblast cells differentiates into amniotic membrane that lines the amniotic cavity.

Day 9- C

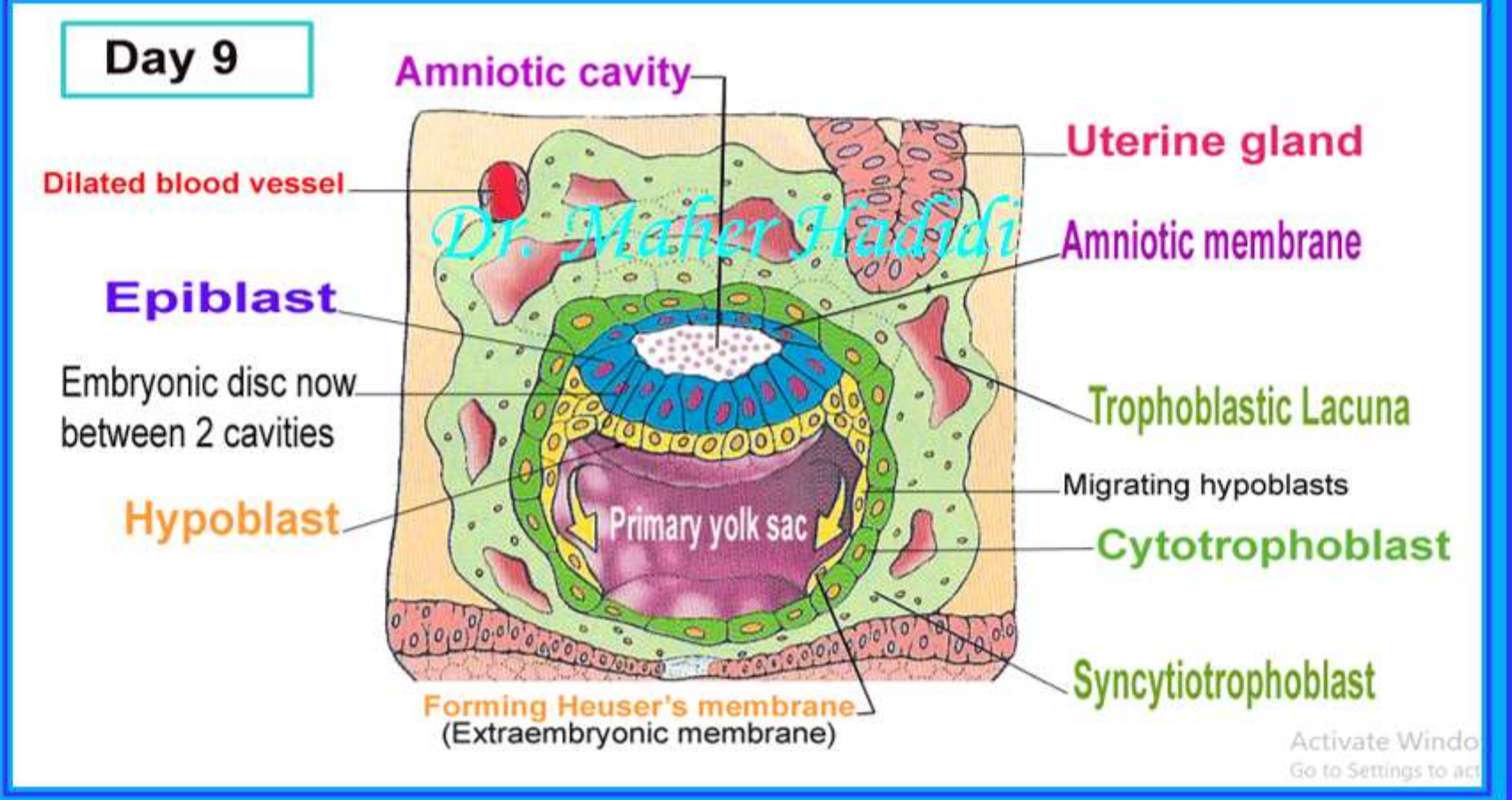

4. Embryonic disc now, lies between Amniotic cavity and Primary Yolk sac.
5. **At the same time**, waves of hypoblast cells migrates down to lines the inner surface of cytotrophoblasts and form the Heuser's membrane. This membrane encloses the primary yolk sac.

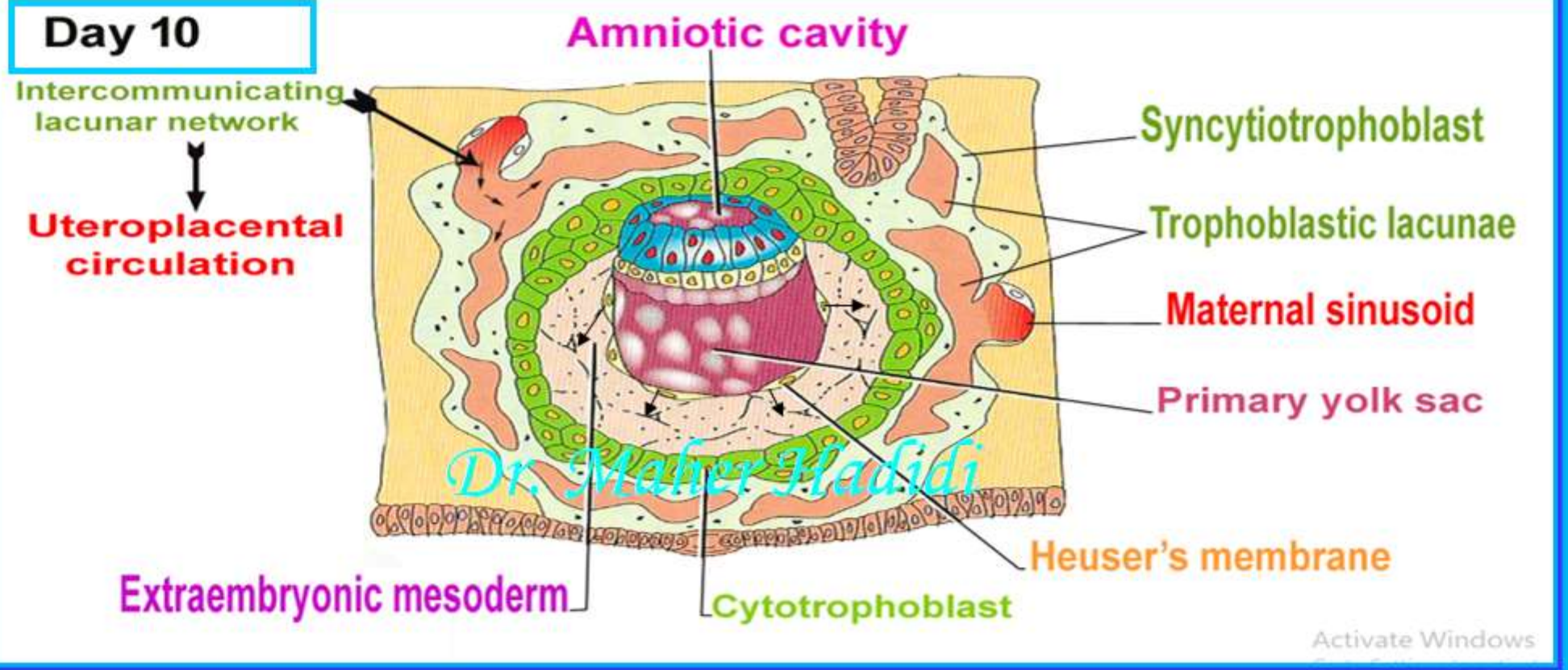

1. As the syncytial cells penetrate deeper, they **erode** the wall of maternal sinusoids and allow maternal blood to flow through the trophoblastic system. This efficient method, establish the **uteroplacental circulation** which, permits the exchange of gases and metabolites by diffusion.
2. Heuser's membrane forms the **extraembryonic mesoderm** externally and fill the space between it and the cytotrophoblast.

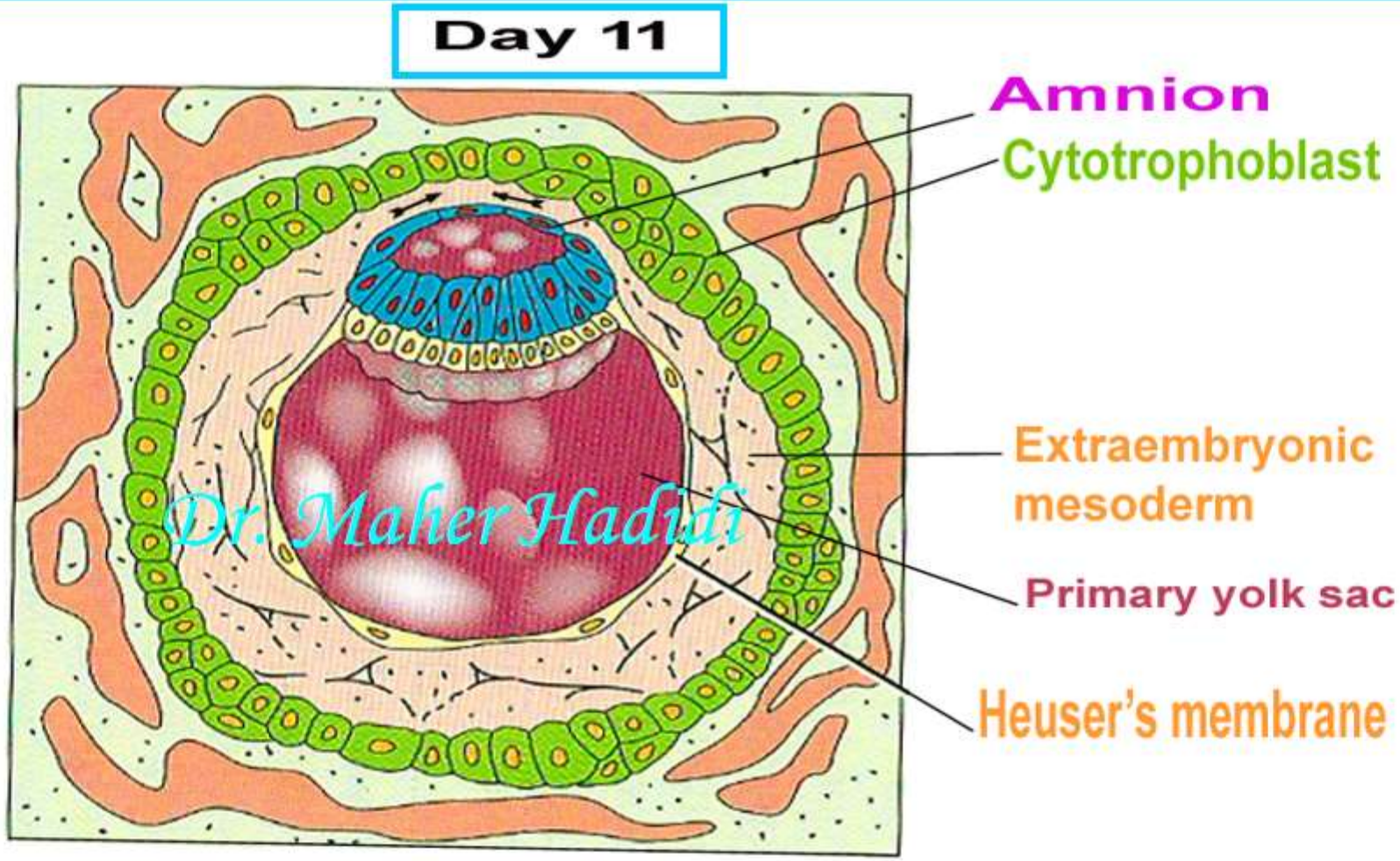

- About **Day 11**, the extraembryonic mesoderm fills the whole space between cytotrophoblast externally and the Amnion as well as the 1ry yolk sac internally.

Day 12

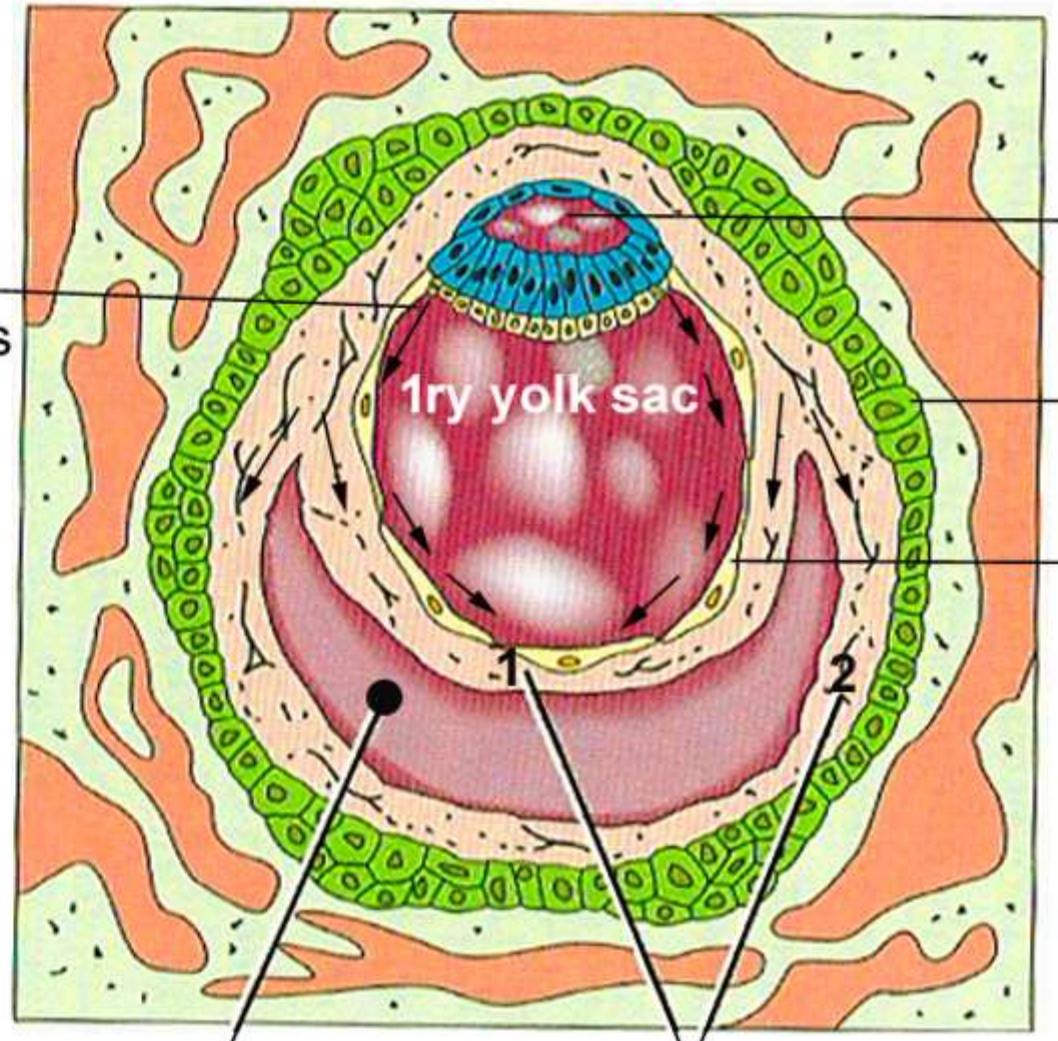
Amniotic cavity
Migrating hypoblasts
1ry yolk sac
Cytotrophoblast
Heuser's membrane
1
2
Chorionic cavity
Extraembryonic mesoderm

Day 13- A

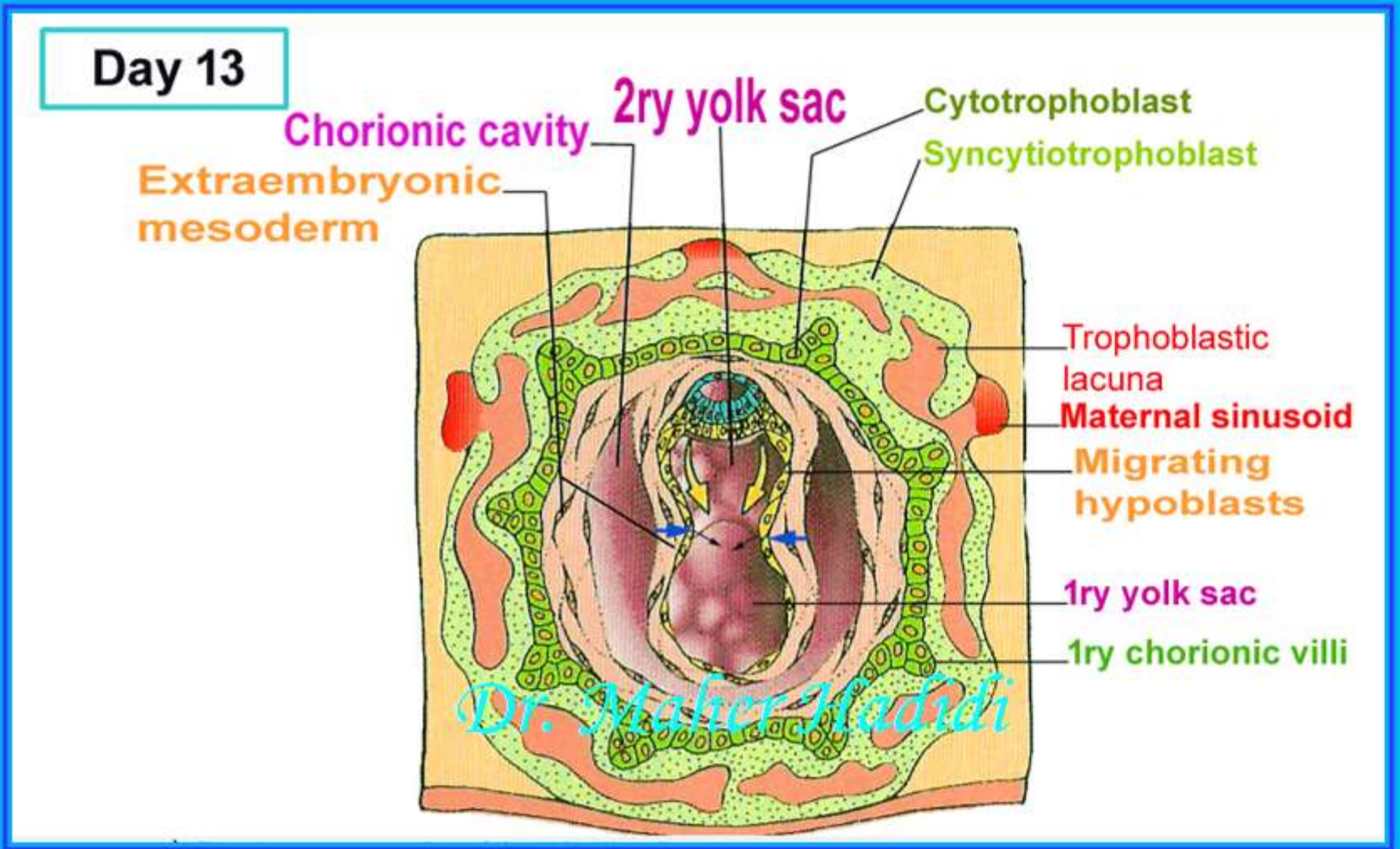

1. On **Day 13**, a 2nd wave of hypoblast cells migrate along the inside of the Heuser's membrane.
2. These cells proliferate and form the small **2ry yolk sac** by pinching off a large portions of the 1ry yolk sac that finally degenerates.

Day 13- B

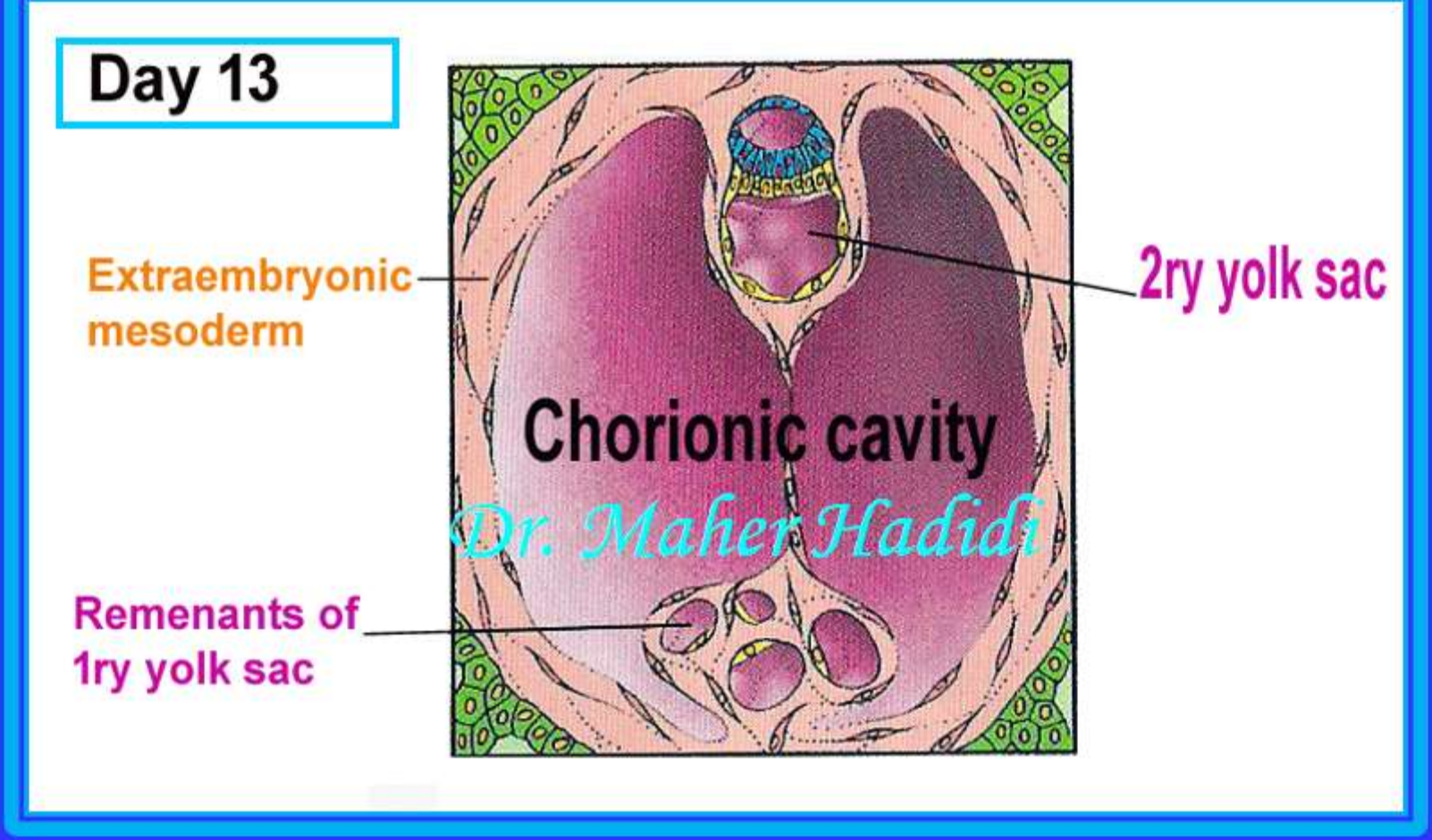

3. The 1ry yolk sac will be represented by a small cysts.
4. Subsequently, a large **chorionic cavity** is formed.

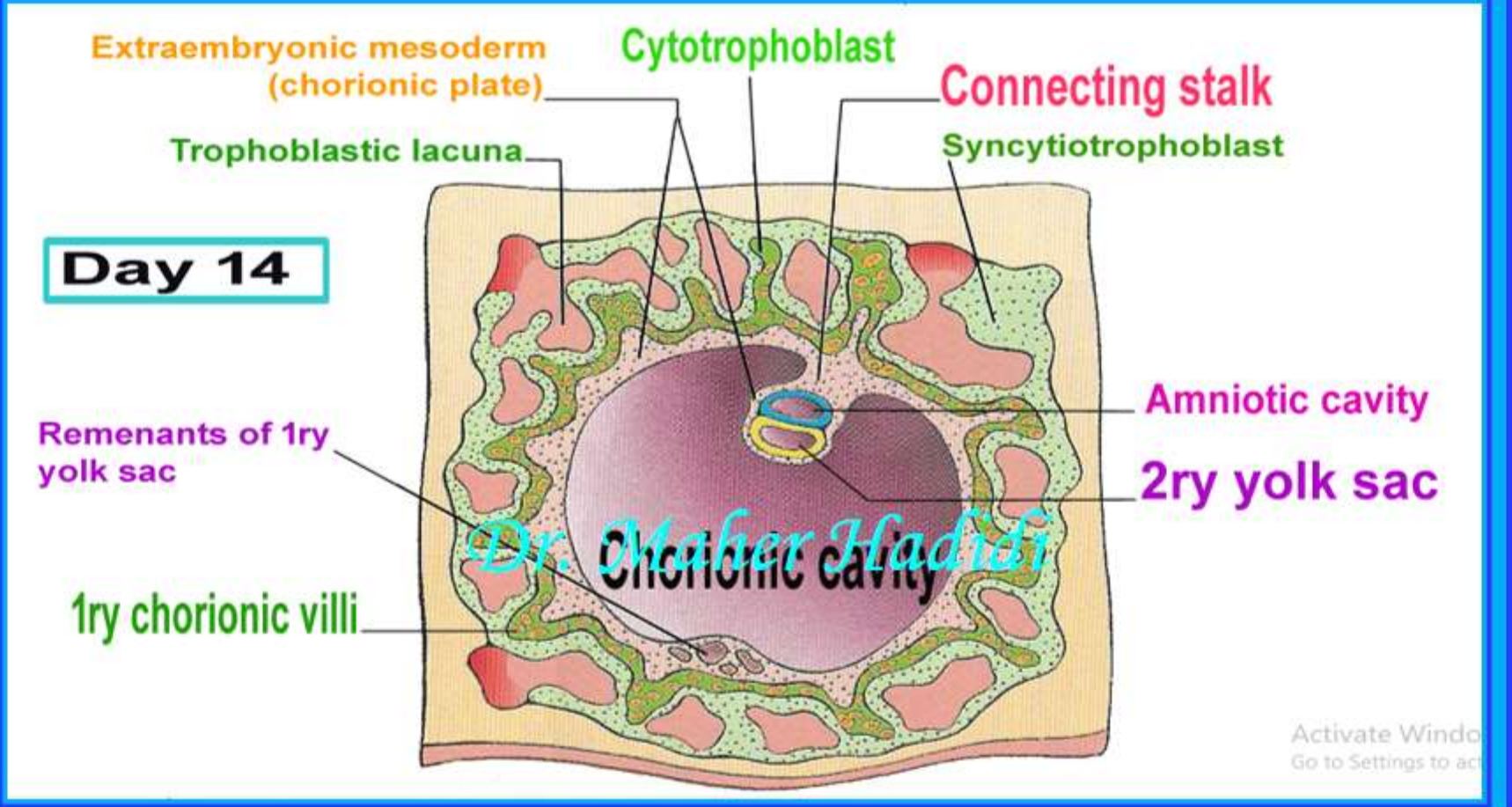

- By the end of the 2nd week, the bilaminar embryonic disc is suspended inside the chorionic cavity and only connected to the trophoblast by a **band of mesoderm** called the **connecting stalk** (future umbilical cord).

End of 2nd week show:

1. Implantation defect healed.
2. Connecting stalk formed.
3. 2ry yolk sac formed.
4. Chorionic cavity formed.
5. 1ry chorionic villi formed.
6. **Implantation Bleeding** refers to a slight bleeding from the implantation site occurs at the end of 2nd week!.

- Women unfamiliar with this incident may interpret as a light menses.

  Day 28 of normal cycle!

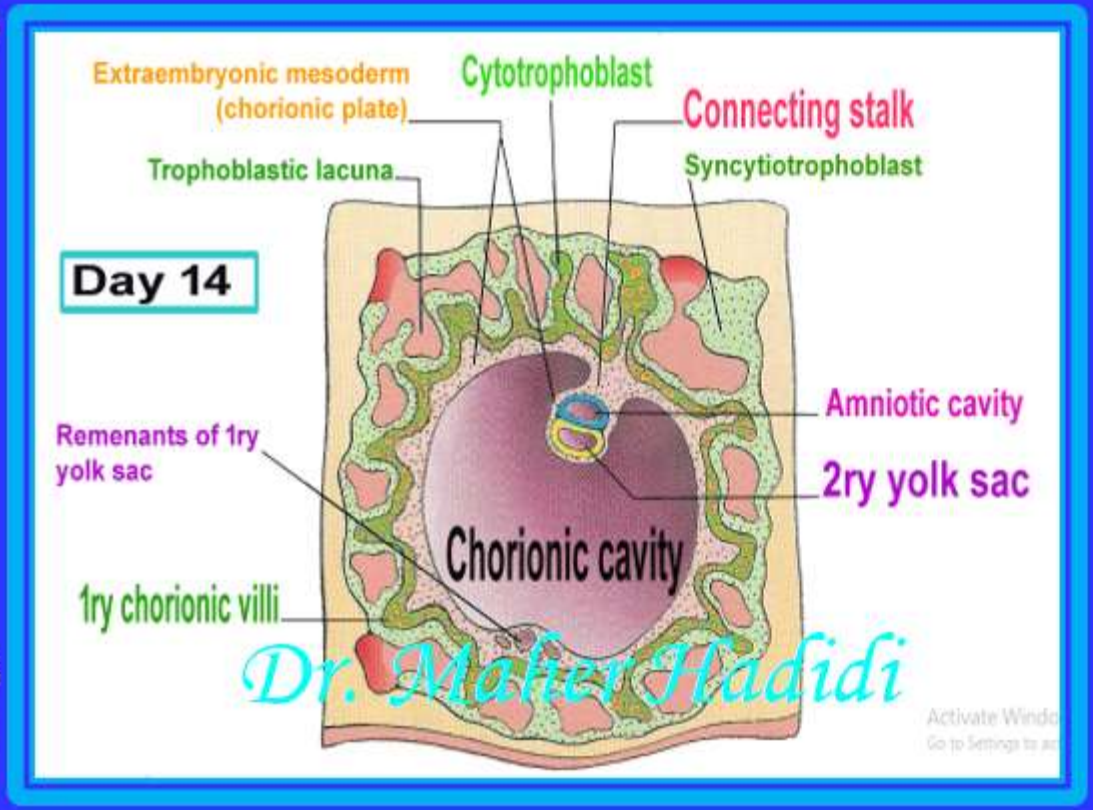

Third week embryo

Third week manifest the following:

- Beginning of embryonic period 3rd - 8th week.
- The week of the first missed menstrual period.
- Rapid development of embryo.
- Gastrulation:
  - A process of converting the Bilaminar embryo into a trilaminar embryo with three definitive germ layers:
    1. Ectoderm
    2. Endoderm
    3. Mesoderm

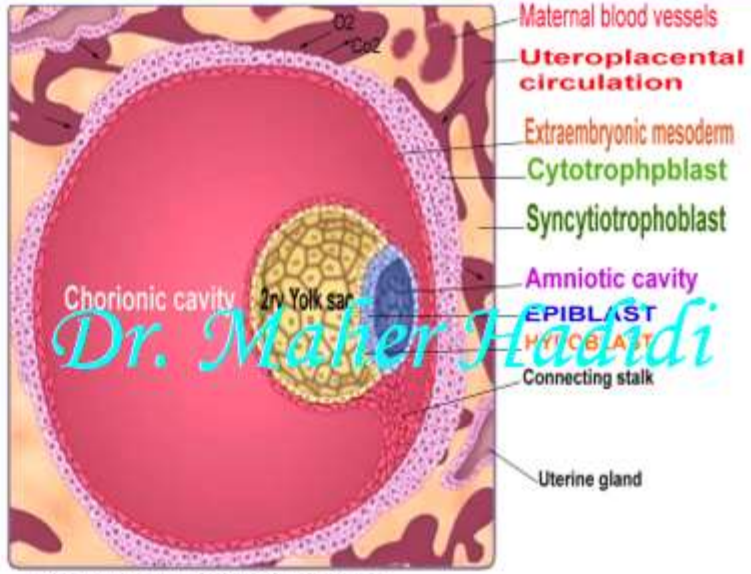

Bilaminar embryonic disc by the end of 2nd week.

Primitive streak formation

Gastrulation begins with the formation of the **primitive streak** on the surface of the epiblast.

Around Day 15,

Epiblast cells speed up their formation and migrates to the **center** of the embryo to form two hilltops with a groove in between called the **Primitive Streak**.

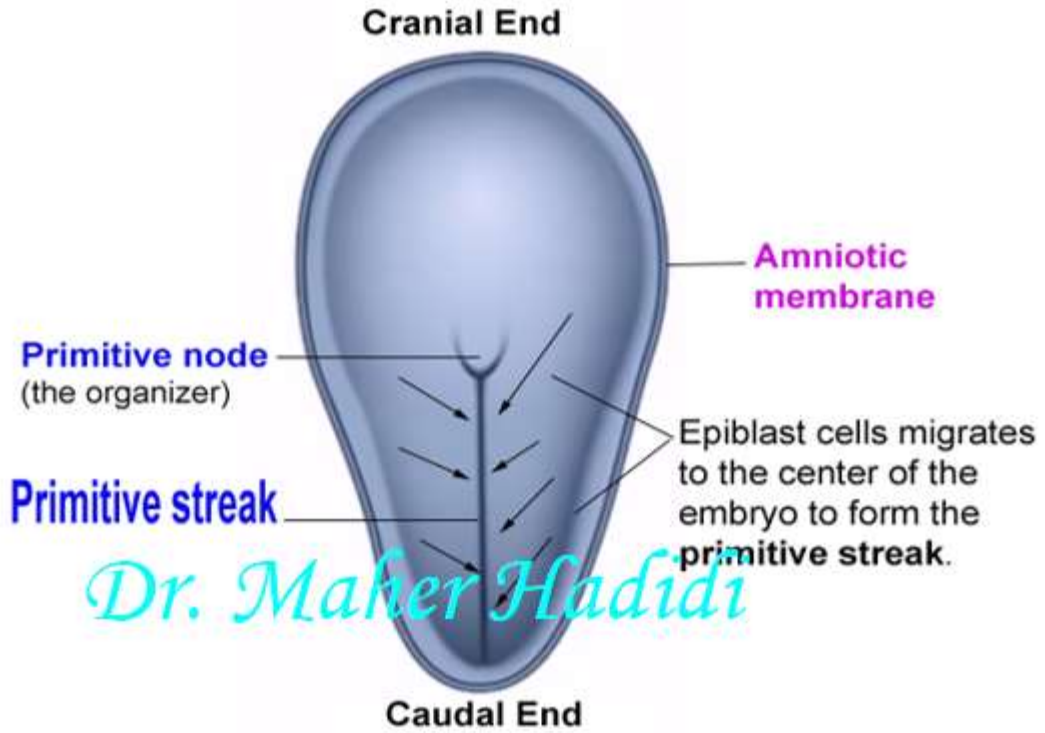

(Superior view of embryo during the 3rd week)

Primitive streak

Primitive Streak appears **caudally** and grow cranially in the median plane of the dorsal aspect of the embryonic disc.

It define the cranial end and the caudal end of the embryo.

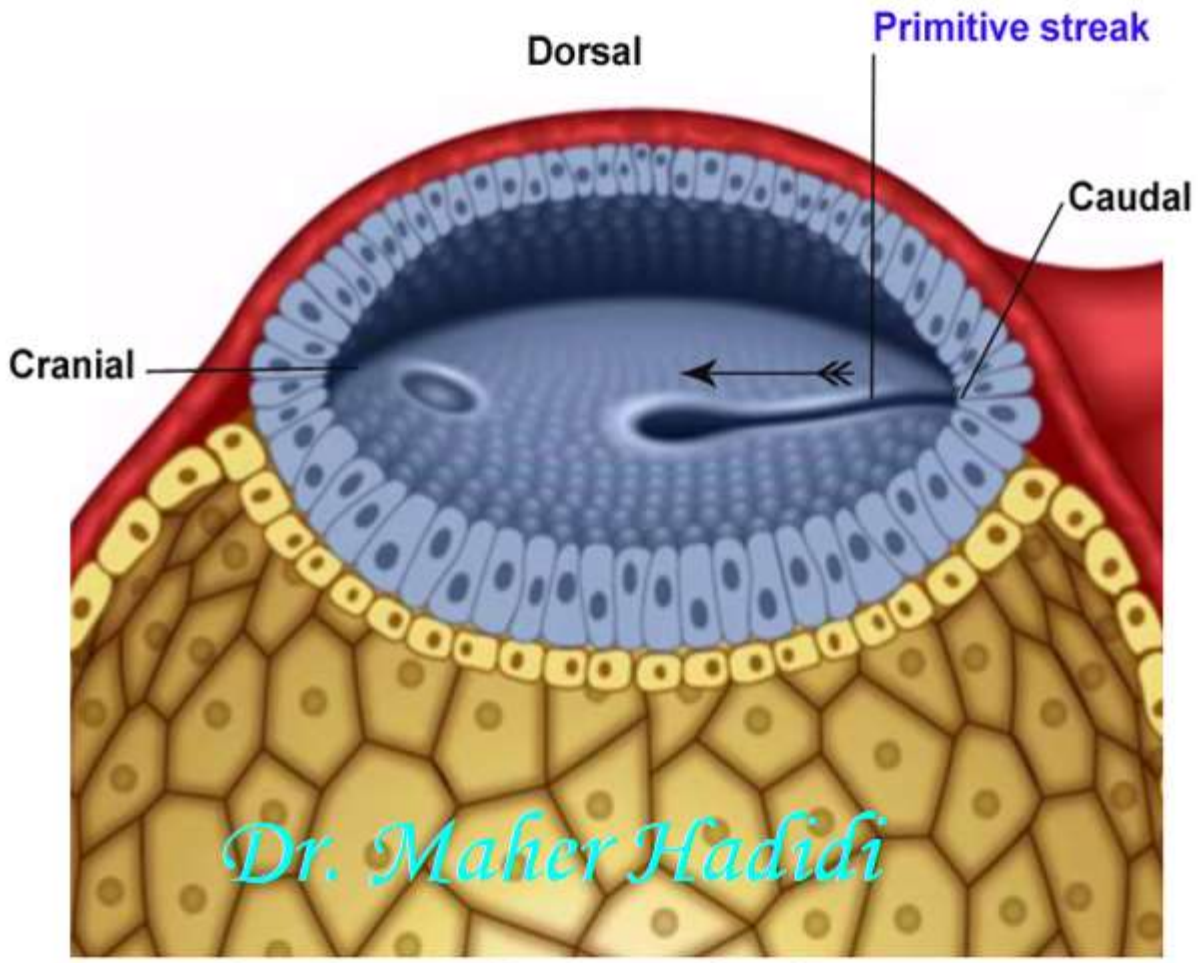

Dorsal aspect of embryo at Day-15

Third week.. continued

1. Some primitive streak epiblast cells invaginated down and displace the hypoblast cells and form the definitive **Endoderm.**

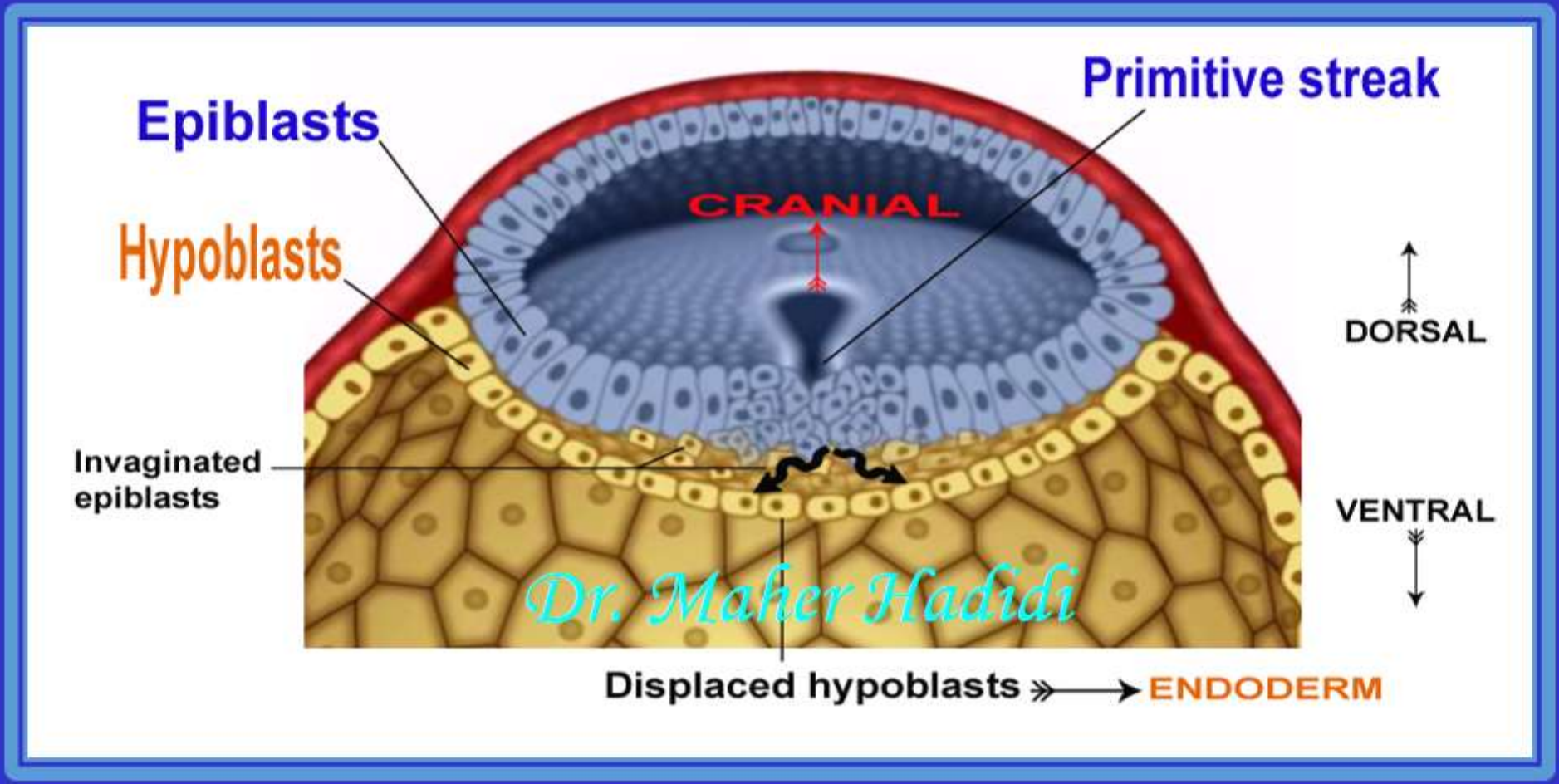

2. Another epiblast cells from primitive streak invaginates between epiblast and hypoblast to give the **Mesoderm.**
3. The remaining epiblast cells, form the definitive **Ectoderm.**

➢ **Epiblast of Primitive streak is the source of all germ layers in the embryo.**

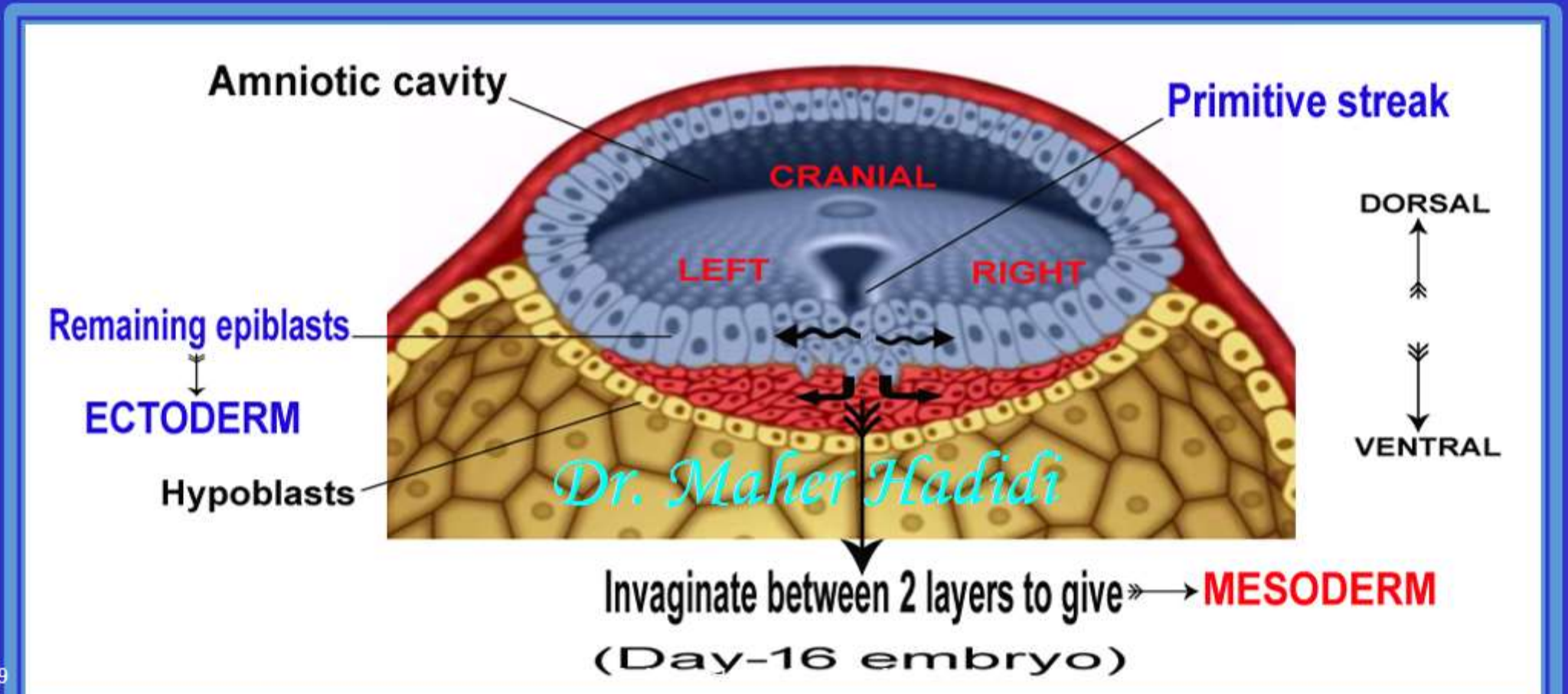

Derivatives of the three germ layers

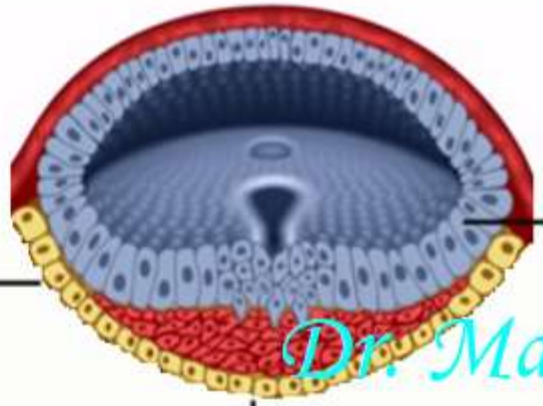

ENDODERM

1. Epithelium of GIT.
2. Epithelium of Respiratory system
3. Liver
4. Pancreas
5. Thyroid gland
6. Tonsils
7. Parathyroid glands
8. Urinary bladder

MESODERM

1 . Bones
2 . Muscles
3 . Connective tissue
4 . Dermis of skin
5 . Primitive heart, Blood vessels, Lymphatic vessels, Blood and Lymphatic cells
6 . Spleen
7 . Serous membranes, pleura, peritoneum.
8 . Urinary system, including ducts and acessory glands
9 . Genital system, including ducts and acessory glands

ECTODERM

NEUROECTODERM

1. Central nervous system
2. Peripheral nervous sys.
3. Retina
4. Posterior part of pituitary gland.

SURFACE ECTODERM

1. Epidermis
2. Hair
3. Nails
4. Mammary gland
5. Internal ear
6. Lens of eye
7. Anterior part of piuitary gland.

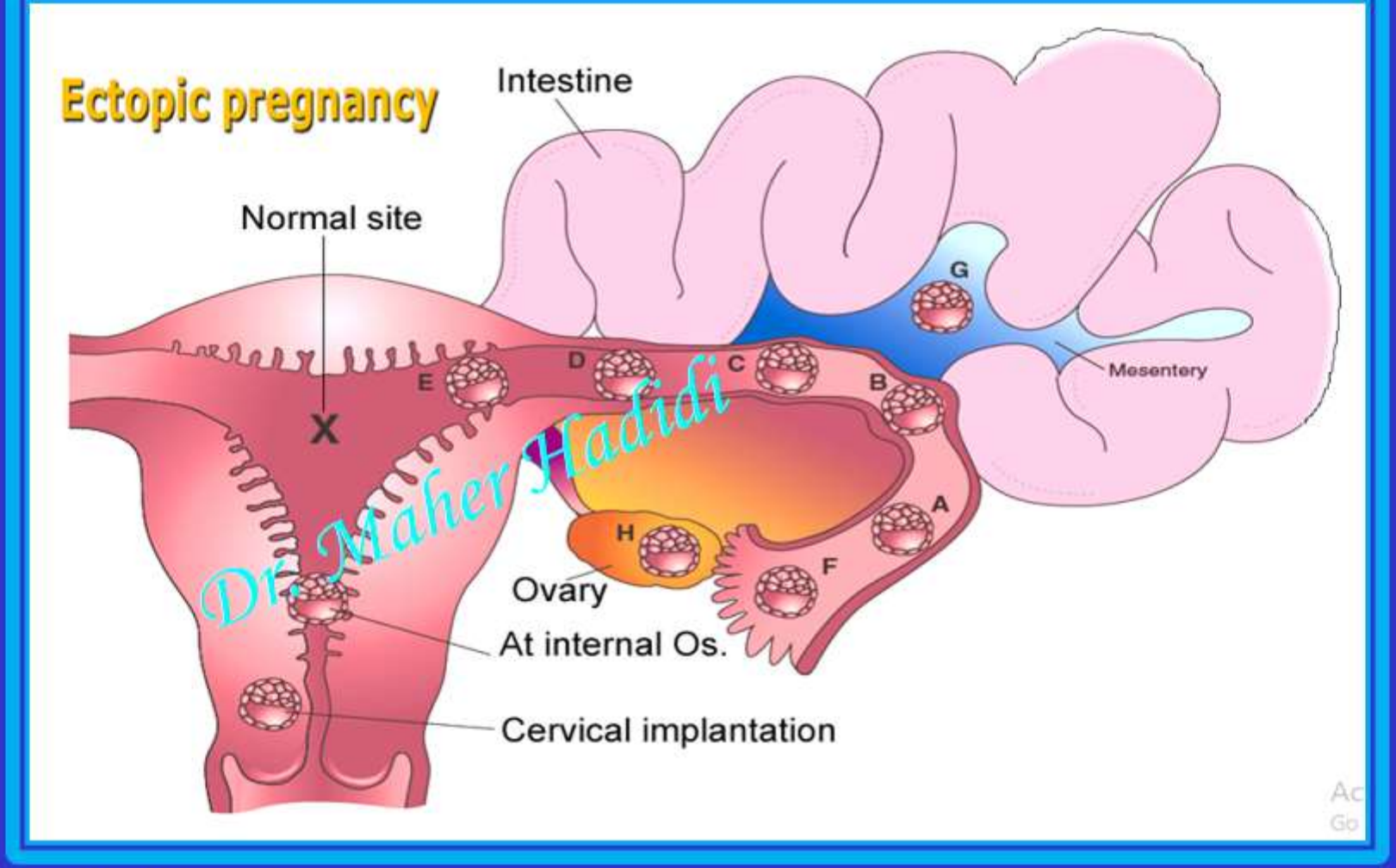

Implantation outside the uterus.

- The approximate order of frequency of ectopic implantations is indicated alphabetically (A, most common, H, least common.
- **Tubal pregnancies** are the most common type of ectopic pregnancy.